

ANALYSIS OF CLINICAL AND HEMATOLOGICAL PROFILE IN PATIENTS HAVING MONONUCLEAR INFILTRATION IN BONE MARROW

Muhammad Ihtesham Khan¹, Saman Waqar², Sunia Arif Khan³

¹Department of Hematology, Khyber Medical College, Peshawar - Pakistan

²Department of Chemical Pathology, Federal Medical Dental College, Islamabad - Pakistan

³Department of Histopathology, Khyber Medical College, Peshawar - Pakistan

ABSTRACT

Objective: To analyze the pattern of clinical features and haematological parameters in patients having mononuclear infiltration as diagnosed through bone marrow aspirate and trephine biopsy examination.

Material and Methods: This chart review was conducted using record of bone marrow biopsy done in Khyber Teaching Hospital during January 2016 to June 2019. The patients of both genders and all ages having mononuclear infiltration in the bone marrow aspirate and trephine biopsy were included in the study. The demographic data, clinical features and basic haematological parameters of patients were noted in a Proforma. Standard deviation and mean were used to analyze quantitative variables. Percentages and frequency were used to analyze qualitative variables.

Results: Out of 556 bone marrow biopsies, about 30 cases were diagnosed as having mononuclear infiltration. Age range of those patients ranged from 6 months to 78 years. Mean age was 29.35 ± 7.3 years. There were 22 (73%) males and 8 (27%) females. Male to female ratio was 2.7:1. The commonest clinical features observed in patients of mononuclear infiltration included fever (seen in 50% cases), and pallor (seen in 56% cases). The commonest indication for bone marrow were pancytopenia and bicytopenia (seen in 40% and 33% cases respectively). The significant findings in haematological parameters were low hemoglobin i.e anemia (seen in 86.6% cases) and thrombocytopenia (seen in 6% cases). The trephines were not available in 17 cases, while in the remaining 13 cases, 7 (53%) trephine samples had atypical infiltrate, while 6 (47%) trephines were hypocellular.

Conclusion: Patients with mononuclear infiltration in their bone marrow present as fever pallor, a low hemoglobin and a low platelet count on their blood count. So constellation of these findings should prompt the physician to keep mononuclear infiltration in differential diagnoses and bone marrow biopsy should be advised to rule out this entity.

Keywords: Mononuclear, bone marrow, aspiration, biopsy, thrombocytopenia.

This article may be cited as: Khan MI, Waqar S, Khan SA. Analysis of clinical and haematological profile in patients having mononuclear infiltration in bone marrow. *J Med Sci* 2020 Jan;28(1):25-28

INTRODUCTION

Mononuclear infiltration in the bone marrow is referred to the metastasis or spread of non haematological tumor cells into the bone marrow from primary tumor site.¹ It is very rare to detect metastatic abnormal cells in the bone marrow smears before the clinical presentation of the primary tumour itself.^{1,2,3} Most of the times, patients with metastasis to the bone marrow have already present-

ed to the clinician with sign and symptoms of the underlying primary tumour. But in certain rare cases, the patients have no specific symptoms of the underlying primary tumour, and the presence of atypical non haematological tumour cells in the bone marrow is the first thing to be identified.¹ This prompts the physician to search for the primary tumour.¹ Patients having metastatic involvement of the bone marrow may be symptomatic or asymptomatic.^{4,5,6} In symptomatic cases, patients present with bone pains, fractures and symptoms related to primary tumour site.⁶ In rare cases, patient may be asymptomatic.⁶ Such asymptomatic cases may have anemia or pancytopenia as detected on blood complete count analysis.⁵ In such cases, the blood counts do not improve by the use of multivitamin and iron supplements.^{5,7,8} In certain very rare cases, basic haematological parameters are near normal despite presence of abnormal metastatic cells in the bone marrow.⁵ Bone marrow aspiration biopsy is a valuable tool to determine presence or absence of atypical cells

Correspondence

Dr. Muhammad Ihtesham

Assistant Professor

Department of Pathology

Khyber Medical College - Peshawar - Pakistan

Email: ihteshamkhan9@yahoo.com

Cell: +92-335-9545329

Date Received: November, 27, 2019

Date Revised: January, 20, 2020

Date Accepted: February, 20, 2020

in the bone marrow.⁹ It also helps differentiate leukemias and lymphomas from non hematological tumour cells that has metastasized from some other primary site.⁹ Both the bone marrow aspiration and trephine biopsy are essential because sometimes, tumors are associated with fibrosis of the bone marrow.² This causes the suppression of the normal hematopoiesis, leading to a dry tap or hypocellular aspirate.² In such cases, bone marrow trephine biopsy proves to be a useful tool in diagnosis.² Very few studies have been done in Pakistan about clinical and hematological profile in patients diagnosed with mononuclear infiltration via bone marrow aspiration examination as the first presentation.^{8,9,10} So, the present study was done in order to determine the clinical presentation and patterns of changes in haematological parameters in cases where mononuclear infiltration is first detected on bone marrow aspiration examination.

MATERIAL AND METHODS

It was a chart review using bone marrow biopsy record. It was done in Khyber Teaching Hospital Peshawar, Pakistan. The study was done from January 2016 to June 2019. Patients presenting to the Pathology department were subjected to the bone marrow aspiration biopsy. All patients of both sexes and all ages having metastatic infiltration in the bone marrow aspiration and biopsy were included in the study. Data regarding age, gender, indication for biopsy, clinical features and hematological parameters were collected on a proforma and analysed. Percentages and frequencies were used for qualitative variables. Standard deviation and mean were used for quantitative variables.

RESULTS

Age range of the population was 6 months- 78 years. Mean age was 29.35 ± 7.3 years. There were 22 (73%) male patients and 8 (27%) female patients. Thus the ratio of the male to female population was 2.7:1. Clinical features and signs of the study sample having mononuclear infiltration are shown in figure 1 and 2 respectively. The indication of bone marrow is shown in Table 1. The hematological parameters in cases of mononuclear infiltration is shown in Table 2.

DISCUSSION

In this study, mononuclear infiltration was found to be common in young adults. Similar findings were reported by Chauhan K in 2016 from India and Syed NN from Karachi.^{2,11} However a higher age was reported by Kumar

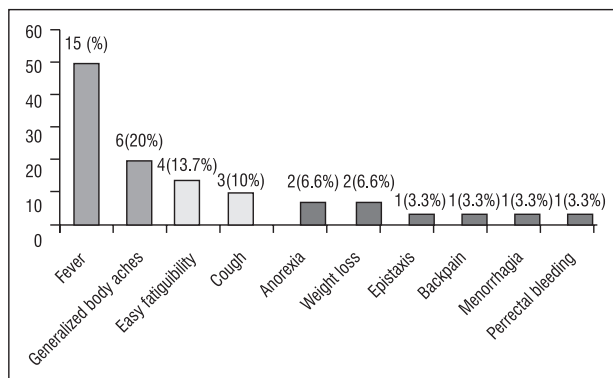


Figure 1: Clinical features of cases with mononuclear infiltration (n=30)

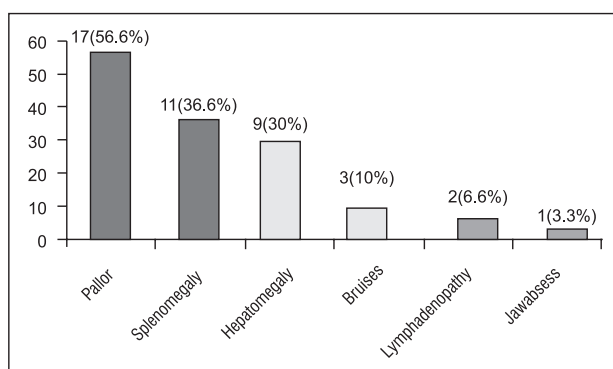


Figure 2: Clinical signs in cases with mononuclear infiltration (n=30)

Table 1: Indications / Suspected diagnosis of bone marrow in cases having mononuclear infiltration (n=30)

Indications of Bone marrow (suspected diagnosis)	No of Patients and % ages
Pancytopenia	12 (40%)
Bicytopenia	7 (23.3%)
Suspected Leukemia	2 (6.6%)
Workup anemia	2 (6.6%)
Suspected Lymphoma	2 (6.6%)
Suspected Multiple myeloma	1 (3.3%)
Miliary Tuberculosis	1 (3.3%)
Rule out malignancy	1 (3.3%)
Suspected Immune thrombocytic purpura	1 (3.3%)

Table 2: Hematological parameters in patients with mononuclear infiltration (n=30)

Hematological parameters	Mean ±SD	Normal n (%)	Range	Decreased n (%)	Increased n (%)
Total leukocyte count (x103/d L)	10.6 ±2.65	13 (43.3%)	0.3 - 84	14 (46.6%)	3 (10%)
Hemoglobin (gm/dL)	8.67 ±2.16	4 (13.3%)	3-14	26 (86.6%)	0 (0%)
Platelet count (x103/dL)	115.4 ±28.8	6 (20%)	0-877	23 (76.6%)	1 (3.3%)

V in 2019 from India, Meenai FJ in 2018 from India, Akhter S in 2018 from Kashmir, and Tyagi from Iran, and Qureshii A from Lahore.^{1,6,9,5,8} This data suggests that there is a wide range of age distribution in cases with mononuclear infiltration .

In this study, it was seen that mononuclear infiltration is common in males as compared to females. Similar male predominance is reported by Chauhan K from India and Syed NN from Karachi.^{2,11} Similar male predominance is reported by different studies done so far.^{1,8,9} However, Meenai FJ from India has reported that female population was more as compared to males.⁶

In the present study, the commonest symptom were fever, generalized body aches and easy fatigability while the the common signs were pallor, splenomegaly and hepatomegaly. Similar findings are suggested by, Syed NN from Karachi, Kumar V from India, Meenai FJ and Chauhan k From India.^{11,1,2,6}

In the present study, the significant changes in hematological parameters included a low hemoglobin level and a low platelet count. Same findings were reported by a Chinese study done by Wang W et al in 2017.¹⁰ Same data is presented by Akhter S from Kashmir, Syed NN from Karachi, Kaur G from India, Zhou MH from China and Kilickap S from Turkey.^{9,12,11,13,14} Kumar V, Meenai FJ, Mehdi SR and Chauhan K from India and Filanovsky presented same data.^{1,2,6,15, 16} The changes in hematological parameters are because of that the metastatic cells replace the megakaryocytes and erythroid precursor cells in the bone marrow.^{17,18,19} The anemia that is caused due to metastatic infiltration of bone marrow is called myelophthistic anemia.^{1,5,20,21,22,23} It is suggested that thrombocytopenia in cases of mononuclear infiltration is associated with poor outcome.¹⁶ A low hemoglobin and platelet count are related to the morbidity and mortality of the patients.¹

As far as the role of pathologist is concerned, it is possible to find the origin of the metastatic tumour with the help of immuno histochemistry.⁸ There are specific immuno markers which when positive can confirm the origin of these cells in the bone marrow. ⁸ But unfortunately, we could not perform it due to unavailability of immuno histochemistry in our department.

LIMITATIONS

It was done in a single hospital. So, there is a need to do bigger studies in which patients from different hospitals should be included in order to generate more accurate data. Secondly, we did not use immuno histochemical stains to find origin of metastatic cells owing to the non availability of this facility in our institute.

CONCLUSION

Patients with mononuclear infiltration in their bone

marrow present as fever and pallor, and have a low hemoglobin and a low platelet count. So constellation of these findings should prompt the physician to keep mononuclear infiltration in differential diagnoses and bone marrow biopsy should be advised to rule out this entity.

ACKNOWLEDGEMENT

All glories be to Almighty Allah for helping me complete this manuscript .

REFERENCES

1. Kumar V, Sardana R, Kishore M, Marwah S, Nigam AS , Bhardwaj M. Bone Marrow Cytomorphology And Clinico-Hematological Profile of Metastatic Solid Tumors: A 5-Year Audit from A Tertiary Care Centre in Northern India. *Annals Path Lab Med.*2019; 6(3):129-34
2. Chauhan K, Jain M, Grover S, Shukla P, Rusia U, Grover RK. Bone marrow metastasis in nonhematologic malignancies: Data from a cancer hospital. *Clin Cancer Investig J* .2016;5:103-9
3. Mishra P, Das S, Kar R, Jacob S E, Basu D. Non-haematopoietic malignancies metastasizing to the bone marrow: A 5 year record-based descriptive study from a tertiary care centre in South India. *Indian J Cancer* 2014;51:30-4
4. Bhopal T, Hussain A, Mallikarjun S, Lakshmi S, Sinha S. Bone marrow infiltration by nonhematopoietic small round cell tumors: A clinicopathological study from a tertiary care centre in South India. *Indian J Med Paediatr Oncol* 2019;40,Suppl S1:1-5
5. Tyagi R, Singh A, Garg B, Sood N. Beware of Bone Marrow: Incidental Detection and Primary Diagnosis of Solid Tumours in Bone Marrow Aspiration and Biopsies; A Study of 22 Cases. *Iran J Pathol.* 2017; 13 (1): 78-84.
6. Meenai FJ, Ojha S, Ali MA, Jain R, Sawke N . Bone Marrow Involvement in Non-Hematological Malignancy: A Clinico-pathological Study From a Tertiary Hospital. *Annals Path Lab Med.* 2018;5(5):440-6
7. Carlsen PF, Hess S, Werner TJ, Alavi A. Cancer metastasizes to the bone marrow and not to the bone: time for a paradigm shift!. *Eur J Nucl Med Mol Imaging.* 2018; 45(6): 893-97.
8. Qureshi A, Shams U, Akhter A, Riaz S. Metastatic Bone Disease as Seen in Our Clinical Practice - Experience at a Tertiary Care Cancer Center in Pakistan. *Asian Pacific J Cancer Prev.*2012.13 (9), 4369-71
9. Akhter S, Khan SP, Geelani S, Bhat S, Hussain S, Akhter S et al. Bone marrow involvement in non hematological malignancies: A clinicopathological study from a tertiary care centre of Kashmir valley. *Int. J. Adv. Res.*2018. 6(9), 278-81
10. Wang W , Peng X , Liang C , Chen H , Zhang Y , Sun X et al. Comparison of Hematological Aspects between Neuroblastoma Patients with and without Bone Marrow Infiltration. *Ann Clin Lab Sci* .2017 :47(4): 416-21
11. Syed NN, Moiz B, Adil SN, Khurshid M. Diagnostic importance of bone marrow examination in non-hematological disorders. *J Pak Med Assoc.* 2007;57(3):123-5.
12. Kaur G, Basu S, Kaur P, Sood T. Metastatic Bone Marrow Tumors: Study of Nine Cases and Review of the Literature. *J*

- Blood Disord Transfus.2011; 2(3):110.
13. Zhou MH, Wang ZH, Zhou HW, Liu M, Gu YJ, Sun JZ. Clinical outcome of 30 patients with bone marrow metastases. *J Can Res Ther* 2018;14, Suppl S2:512-5
 14. Kilickap S, Erman M, Dincer M, Aksoy S, Harputluoglu H, Yalcin S . Bone marrow metastasis of solid tumors: Clinicopathologicalevaluation of 73 case *Turk J Cancer*. 2007; 37 (3): 85.
 15. Mehdi SR, Bhatt ML. Metastasis of Solid Tumors in Bone Marrow: A Study from Northern India. *Indian Journal of Hematology and Blood Transfusion*. 2011; 27 (2,): 93–95.
 16. Filanovsky K, Feldberg E, Miller EB, Shvidel L. Predictive Value of Clinical and Laboratory Parameters for Overt Bone Marrow Metastasis in Patients with Solid Malignancy. *Journal Can Therapy*. 2017; 8(8):773-84.
 17. Naeem R, Naeem S, Sharif A, Rafique H, Naveed A. Acute myeloid leukemia; demographic features and frequency of various subtypes in adult age group. *Professional Med J*. 2017;24(9):1302-5.
 18. Khan MI. Acute Myeloid Leukemia: Pattern of Clinical and Haematological Parameters in a Tertiary Care Centre. *Int.j. pathol*.2018;16(2):90-5
 19. Angelo GD, Hotz AM. Myelophthisis in breast cancer. *Am. J. Hematol*. 2011;86(1):70-1.
 20. Khan MH, Patel A, Patel P, Patel P, Guevara E. Myelophthisic Anemia in a Patient with Lobular Breast Carcinoma Metastasis to the Bone Marrow. *Cureus*. 2018; 10(11):3541.
 21. Munir AH, Khan MI. Pattern of basic hematological parameters in acute and chronic leukemias. *J Med Sci* 2019; 27: (2): 125-9.
 22. Moussavi F, Hosseini SN, SaketS ,Derakhshanfar H. The First CBC in Diagnosis of childhood acute lymphoblastic leukemia. *Int J Med Invest*. 2014; 3(1): 9-12
 23. Pérez JC, Arellano G, Garza JL, Rivera LJ, Almaguer D. Revisiting the complete blood count and clinical findings at diagnosis of childhood acute lymphoblastic leukemia: 10-year experience at a single center. *Hematol transfus cell ther*. 2019;41(1):57-61.

CONFLICT OF INTEREST: Authors declare no conflict of interest

GRANT SUPPORT AND FINANCIAL DISCLOSURE: NIL

AUTHOR'S CONTRIBUTION

Following authors have made substantial contributions to the manuscript as under

Khan MI: Main Idea.

Waqar S: Literature review, discussion, data analysis

Khan SA: Critical Review, result, compilation.

Authors agree to be accountable for all aspects of the work in ensuring that questions related to the accuracy or integrity of any part of the work are appropriately investigated and resolved.