

HYDATID LIVER DISEASE

Iqbal Haider, Mohammad Humayun, Aliena Badshah, Zahidullah Khan, Mudasser Bangash

Department of Medicine, Khyber Teaching Hospital, Peshawar - Pakistan

ABSTRACT

Hydatid disease (hydatidosis or echinococcosis) is a potentially serious, at times lethal disease caused by cysts containing the larval stages of the *Echinococcus granulosus* (*E. granulosus*) tapeworm (dog Tapeworm).

Adult *E. granulosus* tapeworms infect dogs and other canine animals and then these tapeworm eggs are shed in feces of these infected animals. People become infected by ingesting these eggs. This can occur via hand-to-mouth transfer after handling dogs or objects contaminated with the eggs, or from consuming contaminated food or water.

The larval form of the tapeworm may lodge in various body sites where they form a fluid-filled sac known as hydatid cyst. These cysts contain immature forms of the tapeworm and can increase in size from 5–10 cm or more over a period of time. While some cysts may die, others can remain alive for many years. Cysts also contain 'daughter cysts' which, if released, may spread to other areas of the body.

Keywords: Hydatid disease, Cystic echinococcosis, Alveolar echinococcosis, *Echinococcus granulosus*.

This article may be cited as: Haider I, Humayun M, Badshah A, Khan ZU, Bangash M. Hydatid Liver Disease. *J Med Sci* 2019; 27: (3) 242-256.

INTRODUCTION

Hydatid disease or Echinococcosis is a zoonotic, parasitic disease transmitted to human beings by larval (metacestode) forms of tapeworms (*Echinococcosis*) inhabited in the small gut of carnivore animals. The main culprit parasites responsible for human infections are *E. granulosus* and *E. multilocularis* causing cystic echinococcosis (CE) and alveolar echinococcosis (AE) correspondingly. The minimum presumed worldwide human burden of cystic echinococcosis measures about 280,000 disability-adjusted life years or approximately per annum loss of US 190,000,000 US dollars¹. If untreated or inadequately treated, alveolar echinococcosis is documenting mortality of >90% within 10–15 years of diagnosis in the international literature². The mortality rate from cystic echinococcosis (approximately 2–4%) is less than alveolar echinococcosis but it may show upsurge substantially if medical management are scarce³.

Dr. Iqbal Haider (Corresponding Author)
Assistant Professor
Department of Medicine, Khyber Teaching Hospital,
Peshawar - Pakistan
E-mail: driqbalhaiderkth@gmail.com
Contact: +92 - 313-9696102
Date Received: 14th May, 2019
Date Revised: 20th July, 2019
Date Accepted: 10th September, 2019

MATERIAL AND METHODS

Articles published over a span of 38 years extending from 1981 to 2019 were retrieved and studied for writing the current review article. Keywords comprising Hydatid cyst, Hydatid liver disease, *Echinococcus granulosus*, Cystic echinococcosis, Alveolar echinococcosis were used as boolean search words on search engines including Google Scholar, PubMed, iMediSearch, MedConnect, Medline, Cochrane and MDLinx. Total 92 articles were retrieved during this time period while 5 articles were selected during hand searching. At the end, 39 articles fulfilled our selection criteria. PRISMA guidelines and QualSyst criteria were used in the selection of relevant articles. Data gathered from these 39 articles was reviewed and summarized in this review article.

Cystic echinococcosis (CE)

A single organ involvement is documented in 80% patients, where liver is the predominant organ involved having a solitary cyst (80%) followed by lungs (20%)⁴. The germinal layer of *E. granulosus* creates brood capsules and proto-scolecocytes into a central cavity occupying clear hydatid fluid. This hydatid fluid is bounded immediately by an acellular laminated film followed by host response⁵. There may be "daughter" vesicles of variable dimensions in the vicinity of "mother" or initial

hydatid cyst⁶.

Pathogenesis

Radiologic based Reviews documented that cysts may grow in size from 1–50 mm yearly or may remain static for decades⁷. During course of time, these cysts may also tend to rupture instantly, collapse or even vanish⁸⁻¹¹. These cysts usually are asymptomatic till they avail a specific size and mostly these cysts induce pressure symptoms. Abrupt clinical presentation is mostly the result of instant rupture of these cysts. Liver cysts are documented to grow at a slower pace as compared to lung cysts¹².

Diagnostic tools

Ultrasound (U/S) examination and World Health Organization (WHO) classification: Ultrasound is the modality of choice for the diagnosis of CE involving abdominal organs for the individual as well as community screening and diagnostic purposes¹³. In 1995, the

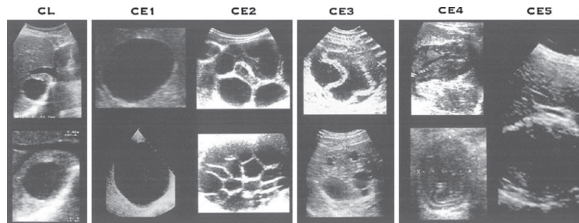


Fig 1: WHO-IWGE classification of CE

Gharbi	I	II	III	IV	V
WHO	CE1	CE3a	CE2	CE4	CE5
CL			CE3b		

Fig 2: Comparison of Gharbi's and WHO-IWGE ultrasound classification

WHO in collaboration with Informal Working Group on Echinococcosis (IWGE) devised a classification system for CE. This classification comprises of: Active CE(CE1, CE2), Transitional CE(CE3) and Inactive CE (CE4, CE5) respectively¹⁴. This classification system proceeds from early to late stages of CE(CE1, CE2 are initial while CE4 /CE5 are late stages of CE infections) (Fig 1).

WHO-IWGE classification is currently widely used classification for CE infections worldwide. This classification is different from that of Gharbi's classification (1981) in following perspectives:(a) addition of undifferentiated stage or cystic lesion (CL), (b) reversing the sequence of CE2 and CE3 and (c) further sub-classifying CE3 into CE3a (havingcysts with detached endocysts) and CE3b (having compact cysts with daughter vesicles) (Fig 2)¹⁵.

Other imaging modalities

Conventional radiography is valuable in the diagnosis of thoracic and bony involvement of CE. MRCP is advised in (i) sub-diaphragmatic setting (ii) disseminated ailment (iii) extra-abdominal position (iv) complicated cysts (e.g; abscess, cysto-biliary fistulae), and (v) pre-op assessment¹⁶.

Direct assessment of E. granulosus and its viability:

Antigen detection of this parasite contributes no effective clue to viability of CE. Similarly calcification per se is not a valid criterion of non-viable cyst(especially CE4/ CE5),however, it may be demonstrable in all phases of CE¹⁷. MR spectroscopy has also been assessed to evaluate viability of cysts in fluid samples obtained either through surgical or percutaneous approach¹⁶.

Serologic modalities:

Table 1: W.H.O. classification of Alveolar echinococcosis.

Strength of recommendation	
A	Good evidence to support a recommendation for use
B	Moderate evidence to support a recommendation for use
C	Poor evidence to support a recommendation
D	Moderate evidence to support a recommendation against use
E	Good evidence to support recommendation against use
Quality of evidence	
I	Evidence from ≥1 properly randomized, controlled trial
II	Evidence from ≥1 well-designed clinical trial, without randomization; from cohort or case-controlled analytic studies; from multiple time series; or from dramatic results from uncontrolled experiments

Hydatid Liver Disease.

Table 2: Stage specific classification of Cystic Echinococcosis.

WHO-IWGE classification	Surgery	Percutaneous treatment (PT)	Drug therapy	Suggested	Resources setting
CE1				<5 cm ABZ	Optimal
				PAIR approach	Minimal
		+	+	>5 cm PAIR + ABZ	Optimal
CE2				PAIR approach	Minimal
			+	Other PT + ABZ	Optimal
	+	+		Other PT	Minimal
CE3a				<5 cm ABZ	Optimal
		+	+	PAIR approach	Minimal
				>5 cm PAIR + ABZ	Optimal
				PAIR approach	Minimal
CE3b				Non-PAIR PT + ABZ	Optimal
	+	+	+	Non-PAIR PT	Minimal
CE4				Wait and watch approach	Optimal
CE5				Wait and watch approach	Optimal

Table 3: W.H.O. classification of Alveolar echinococcosis.

P	Hepatic involvement of AE
PX	Primary lesion can't be evaluated
P0	No detectable hepatic lesion
P1	Peripheral lesions without involving proximal vasculature and/or biliary tract
P2	Central lesions with proximal vascular and/or biliary tract involvement of one lobe
P3	Central lesions with hilar vascular or biliary tract involvement of both lobes and/or with involvement of two hepatic veins
P4	Any hepatic lesion with involvement of the vessels and the biliary tract
N	Extra-hepatic involvement of nearby structures (pleura, lung, diaphragm, heart, pericardium, peritoneum, gastric and duodenal wall, adrenal glands, retroperitoneum, parietal walls of muscles/bone/skin, pancreas, regional lymph nodes, liver ligaments and kidney etc;
NX	Non-evaluable
N0	No regional involvement
N1	Regional involvement of neighboring structures
M	The absence or presence of distant metastasis (spleen, lung, distant lymph nodes, CNS, orbital, bone, skin, muscle, kidney, distant peritoneum and retroperitoneum)
MX	Not completely evaluated
M0	No metastasis
M1	Metastasis

Hydatid Liver Disease.

Table 4: Stage-specific approach to AE.

WHO classification	Surgery	Interventional treatment	Drug therapy	Recommended	Resources setting
P1N ₀ M ₀				Radical resection (R0)	Optimal
	+		+	BMZ for 2 years PET/CT controls Radical resection (R0) BMZ for 3 months	Minimal
P2N ₀ M ₀			+	Radical resection (R0) BMZ for 2 years	Optimal
	+			Radical resection (R0) BMZ for 3 months	Minimal
P3N ₀ M ₀			+	BMZ continuously PET/CT/MRI scan initially and then 2 yearly interval	Optimal
				BMZ continuously	Minimal
P3N ₁ M ₀		+	+	BMZ continuously + PET/CT/MRI scan initially and then 2 yearly interval	Optimal
				Surgery, if indicated	Minimal
P4N ₀ M ₀		+	+	BMZ continuously + PET/CT/MRI scan initially and then 2 yearly interval	Optimal
				Surgery, if indicated	Minimal
P4N1M1		+	+	BMZ continuously + PET/CT/MRI scan initially and then 2 yearly interval	Optimal
				Surgery, if indicated	Minimal

The sensitivity of serologic tests to detect serum antibody for CE (either by indirect hem-agglutination, ELISA, or latex agglutination tests) along with antigen assays in hydatid fluid sample ranks from 85- 98% for hepatic hydatosis, 50–60% for pulmonary and 90–100% for multi-organ hydatosis ⁽¹⁸⁻²⁰⁾.

However, confirmatory tests (like Antigen B, 8 kDa/12 kDa subunits or EgAgB8/1 immunoblotting or Arc-5 test etc) must be performed for doubtful scenarios^{18, 19}).

Treatment of CE

Management recommendations for CE are multi-faceted and depends on hydatid cyst's characteristics, existing medical and surgical competence/ equipment and compliance of patients to follow-up during course of this disease⁽²¹⁾. These treatment options are then graded on the basis of grading system of recommendation and evidence by Infectious Diseases Society of America (IDSA). (Table 1)

Surgical approach for CE

Surgical intervention options for CE include conservative, radical, and laparoscopic modalities ²².

Conservative approaches: it involves: (i) simple tube drainage, (ii) marsupialization, (iii) capitonnage, (iv) de-roofing, (v) partial simple cystectomy and, (vi) open/

closed total cystectomy with/without omentoplasty^{4, 23}.

Radical approaches: Radical approaches comprises of: (i) total pericystectomy, (ii) partial hepatectomy, and (iii) lobectomy²⁴.

Laparoscopic drainage: This is a least invasive, safe and effective approach²⁵⁻²⁷.

Surgery for abdominal cysts:

Indications

To manage complicated cysts, surgery is the first option. The main indications are:

To remove large CE2 and CE3b cysts having numerous daughter vesicles.

Isolated hydatid cyst, located superficially, rupturing either instantly or due to trauma when percutaneous techniques are not available.

Infective hydatid cysts when percutaneous techniques (PT) are non-available.

Hydatid cysts in-communication with the biliary tract (as an alternate to PT) and

Hydatid cysts having pressure effects on nearby vital structures ³.

Contraindications

This option is contraindicated for CE in following

situations:

- General contra-indications for surgery, i.e.,
- Refusal of surgery by Patient
- Extreme geriatric group
- Pregnant ladies
- Patients having severe co-morbid diseases (i.e., DM/HTN, renal, cardiac or hepatic disorders)
- Patients having multiple hydatid cysts
- Difficult to approach these cysts by surgery
- Dead cysts
- Calcified cysts (either partially or totally), and
- Small cysts without pressure symptoms²⁸.

Preferred surgical option

The basic concept of surgical technique is to remove maximally possible parasitic material. However, this aggressive approach increases the operative risk at the cost of lower relapse rate and vice versa²².

Pericystectomy: it may be open or closed technique. *Closed total pericystectomy* carts off these cysts without opening while *open total pericystectomy* first sanitizes these metacestodes with protoscolicidal agents, expels cystic contents and then eradicates these pericystic tissues. The *partial* cystectomy differs by that contents of the cysts are sterilized, removed after opening while the pericyst is only partially resected. Partial cystectomy is appropriate for CE patients living in endemic areas where specialized hepatobiliary surgeons are scarce and surgeries for CE are performed by general surgeons²⁹.

Every possible step should be taken to prevent spillage of cystic fluid. These steps include protection of peritoneal structures with surgical drapes soaked in protoscolicidal agents and protoscolicidal injection inside cyst before opening. A solution of 20% hypertonic saline is usually recommended for this purpose³⁰. This saline solution is recommended to be in contact with the germinal layer of the cyst for a minimum 15 minutes and should be eluded when there is biliary fistula to prevent chemically induced sclerosing cholangitis³¹.

Concomitant drug treatment:

Preoperative treatment is recommended to minimize the hazard of secondary echinococcal infections and should commence at least 4 days prior to surgery and should continue for 4 weeks in case of albendazole (ABZ) or 12 weeks in case of mebendazole (MBZ) therapy. This approach reduces CE intracystic pressure, making it much more convenient for the surgeon to

remove these endocysts^{32, 33}.

Table No. 2: Stage specific classification of Cystic Echinococcosis

Benefits of Surgical approach:

This approach can cure the disease entirely but the risk of relapse is a possibility. The level of evidence on the basis of meta-analytic reviews is low for the surgical management of complicated hepatic and disseminated cystic echinococcosis³⁴.

Risks of Surgical approach for CE:

The risks of surgical approach include general hazards conferred to any surgery (like anesthesia, infections, anaphylaxis, blood-borne and IV transmissible diseases, spillage of active parasitic contents causing secondary echinococcosis (2-25%) and potential risk of relapse if some cysts are left during surgery. Although operative mortality is low (0.5- 4 %) but it is reported to be higher than this in countries with inadequate surgical and medical care facilities^{4, 30}.

Medical requirements for CE management:

The medical personnel must have good competency in treating CE. These patients need admission in hospital having well-equipped surgical units. The economic costs of interventions and post-op health care should be in affording range of affected community³⁵.

Percutaneous treatment approach for CE:

Percutaneous approach is broadly classified into:

Annihilation of the germinal layer (PAIR approach),

Drainage of the entire endo-cyst (a.k.a. Modified Catheterization Technique)³⁶.

PAIR (Puncture/Aspiration/Injection/Re-aspiration) Approach:

PAIR approach for CE treatment comprises these steps: puncture of hydatid cyst percutaneously under ultrasound supervision, maximal aspiration of hydatid cyst fluid, protoscolicidal agent injection (like 20% NaCl or 95% ethanol solution) for a minimum period of 15 minutes and then again re-aspirate the fluid contents of the cyst³⁷.

Indications for PAIR approach:

This approach is indicated in following situations:

Non-operable situations like patients having contraindications or refusal for surgery

An-echoic cysts larger than 5 cm in diameter

Gharbi's type I and type II hydatid cysts³⁸. Hydatid

Hydatid Liver Disease.

cysts laminated with a regular double layer

Gharbi's type III cysts larger than 5 cm in diameter having multiple septation except cysts having honeycomb like characteristics³⁸.

Gharbi's type I, II and III multiple cysts having 5 cm diameter and occupying various segments of liver³⁸.

Post-surgical relapse or response-failure to chemotherapy

Pregnant ladies having symptomatic cysts and

Children less than 3 years old^{37, 39}.

Contraindications of PAIR approach:

Unapproachable or hepatic hydatid cysts located superficially due to hazards of leakage of cystic contents in the abdomen

Cysts having multiple septations (honeycomb-like cysts)

Echogenic cysts

Calcified or inactive hydatid cysts

Communicating hydatid cysts

Pulmonary hydatid cysts^{40, 41}.

Protoscolicidal agents in PAIR approach:

Hypertonic saline solution (5-30% concentration) exhibits scolicidal effect by generating a robust osmotic gradient across the outer layers of protoscolices resulting in their lysis. One of the benefits of this hypertonic saline solution is that it makes CT imaging of hydatid cyst denser and attenuated which clarifies the radiologic assessment of these cysts and making it more elaborate for the physician and radiologist. Few articles are recommending absolute alcohol if cysts are > 6 cm in diameter or type III multi-septated cysts, due to its potent sclerosing, scolicidal and obliterating effects on cyst's cavity^{38, 42-46}. Before initiating PAIR, a four day course of benzimidazoles is obligatory and should be continued for at least 4 weeks in case of albendazole or 12 weeks in case of mebendazole after the procedure^{47, 48}.

Advantages of PAIR approach:

PAIR is slightly invasive and having minimal risk as compared to surgical approach. PAIR endorses CE diagnosis and eradicates significant amount of protoscolices during the process of aspiration of cystic fluid. This approach is economically cost effective in comparison to surgery with minimal hospital stay⁴⁹.

Risks of PAIR approach:

The risks are:

Just like any other aspiration related procedure

(hemorrhage, mechanical trauma to nearby structures, infections),

Anaphylaxis or allergic response due to leakage/spillage of cystic contents and secondary EC. Trans-hepatic puncture of cyst is recommended as puncture of superficial cysts carries a substantial hazard of leakage and spillage.

Chemical induced sclerosing cholangitis,

Abrupt decompression of cysts can result in biliary fistula formation,

Perseverance of satellite daughter cysts.

However, complications pertinent to PAIR at the hands of expertise are infrequent as compared to surgery^{50, 51}.

Medical requisites of PAIR:

The requisites are well-trained PAIR physicians and a proper well-qualified surgical standby team ready to cope with complications⁵².

Follow Up for PAIR:

Serial ultra-sonographic follow-ups following PAIR and ABZ therapy can detect a series of changes in the echopattern of hydatid cysts. Immediately after injecting and aspirating the scolicidal agent, there is dispersion of the germinal layer from the pericyst followed by decline in cyst size, reduction in cyst contents, hardening of inner cyst structure (Pseudo-tumor formation) and in several scenarios, there is ultimate radiographic resolution of these cysts⁵³. Microscopic analysis detects simultaneous perpetual impairment to the germinal membrane enabling to differentiate viable protoscolices from non-viable protoscolices. Both for uni-vesicular and multi-vesicular hydatid cysts, PAIR can be applied by a single needle puncture⁵⁴.

Other Percutaneous modalities:

These techniques tend to be applied for those cysts difficult to aspirate or relapse after PAIR. A good example is CE2/CE3b cysts⁴.

Cysts > 10 cm (Giant cysts) are managed effectively by continuous catheter drainage till their output reaches below 10mL/ day⁵⁰.

The basic aim of these percutaneous procedures is to eradicate the whole endocyst and their daughter cysts from cystic cavity³⁶. This goal can be accomplished by large-bore catheters, cutting and aspiration devices specifically designed for this purpose^{54, 55}. In one study analyzing more than 1000 cases of CE, short/medium-term success rates of these modalities were satisfactory with negligible complication rate^{47, 56}. These treatment options can be effectively utilized for extra-ab-

dominal CE2 cysts⁵⁷. The Strength of recommendation and quality of evidence as per IDSA guidelines is B and III respectively.

C. Anti-parasitic drug treatment:

The main indications for drug treatment of CE are:

Non-operable cases having primary hepatic or pulmonary echinococcosis.

Multiple cysts affecting two or more viscera and peritoneal structures.

Prevention of relapses after surgery or PAIR³².

Pre-surgical use can diminish the hazard of relapse of CE and can make the surgery easier by reducing the intracystic pressure⁵⁸.

The main contra-indications of chemotherapy are:

Big cysts have the tendency to rupture. This risk maximizes if cysts are superficial and infected. Only Benzimidazole (BMZ) therapy is ineffective in hydatid cysts > 10 cm diameter as BMZ is having low potency in cysts having significant fluid collection.

Calcified and inactive hydatid cysts.

Medical disorders significantly compromising liver and bone marrow functions as these medications are hepatotoxic and myelotoxic.

First trimester of pregnancy is a contraindication and chemotherapy in 2nd or 3rd trimester is rarely recommended in the literature. Although literature failed to document any abnormal birth outcome with albendazole in pregnant ladies, usage of ABZ in gravid or potentially gravid women should be very cautious keeping in mind the benefit versus risk ratio⁵⁹.

Medications: Benzimidazoles (BMZ):-

The drug of first choice to treat CE at the moment is albendazole (ABZ) either alone or in combination with PT. It is recommended in a dose of 10–15 mg/kg; body weight daily in two divided doses along with high fat diet to maximize its bioavailability⁶⁰. Albendazole has documented better in-vitro activity, improved pharmacokinetics and better clinical trials in comparison to MBZ. Albendazole after oral administration underwent first-pass metabolism to albendazole sulfoxide (active metabolite), avails variable levels in blood, bile, hepatic tissues, hydatid fluid, and walls of the cysts and then passes through blood-brain barrier. The current concept is to administer ABZ uninterruptedly in contrast to treatment interruptions on monthly basis advocated in 1980's⁽⁶⁰⁾. The previous concept of treatment interruptions was based on the scarcity of long-term data availability regarding toxic effects of ABZ during that

era; however, current literature is not favoring treatment interruptions for CE anymore^{4, 61}.

Important Drug interactions:

Medications that increase the level of ABZ are: dexamethasone, praziquantel, cimetidine and antiepileptic drugs (carbamazepine, phenytoin, and phenobarbital). All these drugs enhance bioavailability of ABZ with increased levels of its active metabolite⁶².

Antifungal drug clotrimazole diminishes in-vitro activity of sulfonase in microsomes inhibiting the formation of active and inactive metabolites of ABZ. In case of non-availability or intolerance of ABZ, mebendazole (MBZ) may be used as an alternative, in 3 divided daily doses of 40–50 mg/kg along with high fat food^{47, 60}.

Other drugs:

Praziquantel (PZQ), another antiparasitic agent, has restricted use in the treatment of hepatic hydatosis. This drug enhances the entry of calcium ions into the cell membrane of parasite, initiating robust muscular contractions and paralysis resulting in detachment of cyst from host tissues. It is an effective scolicalidal agent both in-vitro and experimental animals. In human beings, it has satisfactory drug levels when taken at a dosage of 50 mg/kg; body weight either at every week or every two weeks interval. Various studies have documented the efficacy of combination of PZQ/MBZ or ABZ as compared to BMZ alone⁶³. Marchiondo A has reported non-viable cysts during surgery when patients are treated pre-operatively with combination of ABZ+PZQ therapy⁶⁴. Even few studies have documented the supremacy of combination of PZQ/ABZ over ABZ alone as an effective protoscolicalidal agents, however, the effectiveness of PZQ to prevent relapses needs further research⁵⁸.

Advantages of Chemotherapy:

Chemotherapy is a noninvasive option for patients of all ages, even though limited data is available for children < 6 years age and chemotherapy is least compromised by patient's well-being with the exception of pregnancy in comparison to surgery. Chemotherapy is an outpatient treatment option. Albendazole is more effective in young person having small CE1/CE3a hydatid cysts. However, BMZ are less effective in the management of CE2/CE3b hydatid cysts^{60, 65}. Systematic reviews have confirmed the significance of cyst's stage and size in defining the response to treatment⁶⁶.

Adverse events of chemotherapy:

The adverse events of BMZ are hepatotoxicity (transient rise in aminotransferase levels), neutropenia, thrombocytopenia and alopecia⁶⁷.

Monitoring of patients with CE:

Regular follow-ups along with ultrasonography should be performed initially after every 3–6 months and then on yearly basis once the condition is stable. Serial WBC's and ALT/AST levels monitoring are mandatory at monthly basis to determine adverse events. The dosage of oral medications can be adjusted on individual basis to achieve optimum serum drug levels but only limited labs have competence to measure ABZ/MBZ plasma drug level⁴⁷. The medical and lab assessments of these patients for adverse events are mandatory initially every 2 weeks and then on monthly basis. The WBC counts need monitoring at 2 weekly intervals during the first 12 weeks of therapy as in exceptional scenarios catastrophic and even irreversible myelosuppression has been documented during the initial phase of treatment.

Ideally serum drug levels of ABZ or MBZ should be monitored at 2 and 4 weeks of chemotherapy in order to determine toxic/ineffective drug levels. In case of MBZ, serum drug levels should be monitored 4 hours after the morning dosage. However, this practice is very difficult in poor and developing countries due to higher cost and limited lab facilities to determine drug concentration level. The management of CE requires long-term chemotherapy and evaluation after every 3 months is required to determine efficacy of this chemotherapy⁶⁸. Radiographic imaging should be performed during each follow up⁶⁹.

Management of asymptomatic CE detected during screening:

Mass screening is not recommended on ethical grounds without the consent of community under study and elaborative concept regarding medical care should be offered to individuals having suspicion of CE. If willing, they can undergo specific serologic and clinical assessments for confirmation of diagnosis and selection of those requiring treatment. Infected individuals who are not candidate of urgent treatment needs careful monitoring on regular basis⁷⁰.

Alveolar echinococcosis:

Alveolar echinococcosis (AE) is a dreadful disease due to larvae of *E. multilocularis* and manifested as infiltrative growth mimicking tumor like conditions. Its management evolves around different options including chemotherapy and entails specialized clinical expertise⁷¹. All patients with suspicion of AE needs timely referral to a nearby well- experienced AE treatment center. Prompt diagnosis is of prime significance for proper managements as AE community screening programs in endemic zones of the world have clearly displayed the significance of early diagnosis to minimize

morbidity and mortality of this disease⁷².

Organ involvement in AE:

Primarily, liver is the first organ to be infected by the metacestodes. The right hepatic lobe shows predominance, however, hepatic hilum along with one or two lobes may also be affected. These hepatic lesions may vary in size from few mm to > 15 cm in diameter. Primary extra-hepatic involvement of these metacestodes is extremely uncommon⁷³. These metacestodes of *E. multilocularis* then disseminate from liver to other structures by infiltration or metastasis.

Pathogenesis of AE:

AE infection comprises of initial incubation period of asymptomatic phase lasting from 5-15 years to be followed by chronic course of this disease. The clinical features are usually of cholestatic jaundice and epigastric pain (in approximately 1/3 of cases each) while the remaining (1/3 of cases) AE patients are diagnosed incidentally during medical check-up for lethargy, weight loss, visceromegaly or abnormal lab reports⁽⁷⁴⁾. Literature is reporting high mortality rate amongst non-treated/inadequately treated patients. A clinical report from Germany documented 5 year mortality of 70% and 10 year mortality of 94%⁷⁵. Another study from Alaska reported average survival rate of 5.3 yrs and 100 % mortality within 14 yrs of diagnosis. However, host immune system has capability to degenerate and even kill the larva of AE and these dead calcified lesions can be recognized during mass screening programs^{71, 76, 77}.

Diagnosis of AE:

AE is diagnosed on the following parameters: interpretation of clinical manifestations, epidemiological data and morphology of lesions under imaging modalities in combination with immunological and other lab investigations.

Ultrasound examination:

U/S examination requires competence level. The U/S findings in 70% of cases are:

Correlation of hyper and hypo-echogenic foci in pseudo-tumor having asymmetrical margins and scattered calcification and

Pseudo-cystic morphology comprising of central necrosis bounded by irregular hyper-echogenic rim.

In the remainder 30% scenarios, it may be either Hyperechoic lesion nodule like hemangioma or Calcified focus of dead or tiny parasites^{78, 79}.

CT and other Imaging techniques:

CT imaging gives good results in determining

the anatomical and morphological characteristic of the lesion and its calcification. MR modality may elicit the multi-vesicular appearance of these foci, thus favoring AE diagnosis⁷⁹. MRCP has substituted percutaneous cholangiography to evaluate the correlation of AE lesion and hepatobiliary tract⁷⁹.

Assessment of *E. multilocularis* and its viability:

Histopathology confirms these vesicles to be demarcated by a laminated layer of Periodic Acid Schiff. PCR of biopsy tissues can detect *Echinococcus* specific nucleic acids while RT-PCR may evaluate even viability of these lesions^{80, 81}. FDG-PET scan may indirectly delineate active foci of parasites. When patients are asymptomatic and there is high suspicion of relapse despite normal conventional imaging, these modern imaging modalities in combination with CT (PET/CT) or MRI (PET/MRI) may be helpful to detect active disease^{82, 83}.

Multilocularis serology:

The diagnostic sensitivity and specificity of *E. multilocularis* antigens produced either by purified/recombinant or in-vitro technique ranges from 90–100% and 95–100% respectively⁸¹.

W.H.O. classification of AE:

AE is classified by WHO-IWGE PNM classification system. PNM classification system represents hepatic involvement by the parasitic lesion (P), extension to nearby structures (N) and metastases (M)⁸⁴.

Diagnostic criteria of AE:

At least one of the following four diagnostic criteria is required to diagnose AE:

Distinctive organ lesions identified by imaging techniques (abdominal U/S, CT, MRI)

Detection of *Echinococcus* species specific serum antibodies by high sensitivity serological tests and confirmed by a high specificity serological test

Histopathologic findings compatible with AE

Detection of *E. multilocularis* nucleic acid sequence in a clinical scenario⁸⁴.

Possible versus probable versus confirmed case of AE:

Possible case: A patient having clinical, epidemiologic and imaging features or serologic evidence of AE.

Probable case: A patient having clinical, epidemiologic, imaging features and serologic evidence of AE with two positive tests.

Confirmed case: All the above features and (1) histopathologic findings compatible with AE and/or (2) detection of *E. multilocularis* nucleic acid sequence(s) in a clinical acumen⁸⁴.

Treatment of AE:

The following concepts are generally considered in the management of AE:

Radical surgery of the whole lesion is first option in all operable patients.

Chemotherapy after radical resection is indicated for a limited time.

Chemotherapy of prolonged duration is compulsory if: lesion is incompletely resected, non-operable conditions including post-interventional procedures and post-liver transplant AE patients. Referral to a recognized nearby AE treatment center is advisable and if this is not feasible, treatment should be initiated under the supervision of such center⁸⁵.

Surgery for AE:

The excision of these lesions is conducted by the principle of radical tumor resection. Radical or non-radical resections and liver transplantation needs adjuvant chemotherapy. Radical resection of lesion is the main aim of management. Excision of the whole lesion follows the basics of tumor resection and is classified on the basis of quality of resection: R₀: without residue; R1: microscopic residue; R2: macroscopic residue.

Initially considered to be a beneficial option in reduction of parasitic load, non-radical hepatic surgery confers no advantage over conservative management^{72, 85}.

Parasitic foci not restrained to liver are not considered to be contraindication for surgery but they must fulfill R₀ resection criteria, otherwise, these lesions must be managed by alternative approaches following interdisciplinary integration. Lesions affecting other organs (brain etc;) may undergo either surgery or alternative interventions. All these treatment modalities must be accompanied with adjuvant BMZ chemotherapy for 2 years at least⁸⁶.

Indications of Surgery for AE:

Radiologic assessment of these lesions before surgery is mandatory as lesion's resectability in liver is a prerequisite for radical surgery. These pre-op assessments will determine potential for resection and possibility of dissemination of disease too⁸⁵.

Contraindications of Surgery for AE:

Non-operable disease

Disseminated lesions⁸⁵.

Choice of the surgical techniques for AE:

Radical resection (R₀ resection) is the first choice of treatment. Surgical techniques and modalities adopted in oncology with a concept of 2 cm clear margins are practiced during resection of these parasitic lesions^{64, 87, 88}. All Post-op patients must undergo chemotherapy with BMZ and long-term follow-up. Palliative surgery is not recommended but the diverse characteristics of AE in some instances may pursue this approach. If PT approach fails for a septic focus, then R₀/ R1 or even R2 surgical resection is advised. To treat skin lesions, a combination of palliative resection with adjuvant BMZ is also beneficial⁸⁵. The Strength of recommendation and quality of evidence as per IDSA guidelines is B and III respectively⁸⁵.

Benefits of surgery:

Radical surgery may eradicate these parasites and cure the disease. A timely diagnosis markedly enhances the perspective of cure for AE. Non-radical surgery may be helpful to minimize the parasite load and augment the efficacy of chemotherapy⁸⁹.

Liver transplantation for incurable AE:

Liver transplantation as a treatment option was utilized in 45 cases having incurable AE across 65 hepatic transplant centers in European countries⁹⁰. However, literature is reporting relapse of disease under the influence of immunosuppression⁴⁷.

The main criteria to qualify AE patients for liver transplant (LT) are:

Decompensated liver failure (like secondary biliary cirrhosis/hepatic vein thrombosis) or recurrent episodes of severe cholangitis and

Non-operable radical resection of liver.

Indications for LT in AE infections:

Interdisciplinary integration is mandatory for LT in patients having severe AE with decompensated liver disease and it necessitates long-term post-op chemotherapy⁹⁰.

Contraindications for LT:

LT is contra-indicated in: disseminated AE, AE patients having contraindications for long-term immunosuppression/or adjuvant BMZ⁹⁰.

Benefits of LT:

LT may be a lifesaving approach in patients having severe hepatic compromises.

The survival rate of 5 years with and without

relapse is reported in few studies of approximately 71% and 58% respectively which is encouraging in comparison to HCC⁹¹. Long-term cure is a possibility in AE patients having residual or recurrent disease with adjuvant BMZ therapy^{90, 92}.

Risks of LT in AE:

Risks are same as for general surgery/anesthesia, risks associated with immunosuppression, regrowth and relapse of disease and metastases specifically to CNS during immunosuppressive therapy⁹¹. The Strength of recommendation and quality of evidence as per IDSA guidelines is C and II respectively⁹¹.

Medical requirements for LT:

LT needs state of the art center and well trained highly experienced staff along with back-up medical team having ample experience in post-transplant management⁹³.

Chemotherapy for AE:

Meta-analysis in animals has documented the significance of parasitostatic efficacy of BMZ against metacestodes of *E. multilocularis* and on this basis; chemotherapy in humans for AE is being practiced as early as 1975. Survival rate comparison between patients treated with BMZ and untreated historical cohorts is documenting that 10 year survival rate of treated cohort has augmented from <10% to 85-90%. This improvement in survival is the contribution of chemotherapy together with timely diagnosis, improvisation of surgical and medical care of AE patients⁹³.

Indications of Chemotherapy for AE:

Prolong yearly therapy with BMZ is compulsory for all AE patients having non-operable disease and those having post-resection of the lesions. As the remnants of AE residues after radical surgery/LT may persist undetected, so BMZ therapy is recommended for a minimum 2 years and these cases need monitoring for at least a decade for potential relapse⁸⁶. Pre-surgical chemotherapy is not recommended for AE except in patients having contra-indications for surgery, however, surgery can be pursued after long-term chemotherapy⁹³.

Contraindications of Chemotherapy:

There are few contraindications of chemotherapy and include life-threatening side effects. Pregnant ladies need specific precautions as already discussed⁹³.

Choice of anti-helminthics in AE:

Two BMZ (MBZ and ABZ) are preferentially used for chemotherapy of AE.

The dose of ABZ is same as recommended in CE (10–15 mg/kg. in daily 2 divided doses with high fat diet).

In daily clinical practice, a total dose of 800mg/day is given orally to adults in 2 divided doses. Non-interrupted ABZ therapy for AE is well tolerated and is being in clinical practice for more than 20 years⁹³.

ABZ has been prescribed in higher doses of 20 mg/kg/day for 4-5 years in occasional scenarios. In case of non-availability or intolerance of ABZ, MBZ can be substituted in a daily oral dose of 40–50 mg/kg divided into three doses with high fat diet⁹³. The Strength of recommendation and quality of evidence as per IDSA guidelines is B and III respectively⁹³.

Other Drugs for AE:

PZQ can be an alternative option in AE but animal experimental data is not favoring its efficacy even in very high doses⁶⁴. Conventional or liposomal Amphotericin B has been utilized as an alternative therapy in few cases who were not tolerating BMZ⁹⁴. Nitazoxanide has not documented any efficacy a recent trials⁹⁵. New formulations of ABZ may improve bioavailability, however; further randomized trials are needed to draw definite conclusions regarding these new formulations⁹³.

Benefits of BMZ therapy:

BMZ is a noninvasive option having minimal side effect profile. However, this therapy is parasito-static in most cases⁹³.

Risks of BMZ therapy:

The main hazards of BMZ therapy and its use during pregnancy have already been described in detail.

Medical requirements for Chemotherapy:

Patients can be managed on out-patient basis but regular clinical and lab surveillance is mandatory⁹³.

Pharmacovigilance of Chemotherapy:

Regular follow-ups for adverse events are necessary initially every 2 weeks for first 12 weeks, then on monthly basis for first year and later on every 3 months. As BMZ is mandatory for all AE cases, so if ALT/AST values rises more than 5 times ULN, the following precautions should be followed: (a) evaluate these patients for other causes of rise in aminotransferase levels, (b) monitor drug therapeutic level, (c) if there is higher serum drug level of BMZ in comparison to recommended therapeutic level, minimize the parent drug dosage and switch to available alternative BMZ, and (d) if still aminotransferase values remain above 5×ULN, consultation to a reference center becomes mandatory. A reduction in WBC count below $1.0 \times 10^9/L$ specifies toxicity of BMZ and necessitates urgent treatment withdrawal⁹³.

Interventional options for AE:

AE patients having contraindications for surgery

may develop a variety of complications. These complications can be effectively managed in combination with chemotherapy by interventional procedures like: dilatation/stent implantation in vessels, drainage of necrotic liver lesions and/or bile, and endoscopic sclerosing of esophageal varices⁸⁹.

Indications of Interventional options:

These procedures are indicated if surgical option is impracticable due to involvement and dysfunction of vital structures (i.e. hyper-bilirubinemia due to cholestasis, thrombosis of portal vein/ inferior vena cava, liquefactive necrosis of liver with rupture into abdomen and risk of esophageal varix bleeding due to portal hypertension)⁸⁹.

Contraindications of interventional procedures:

Interventional procedures have the tendency to metastasize this disease and is not recommended if post-procedure chemotherapy is impracticable⁸⁹.

Principles of interventional procedures:

Bile or abscess drainage by percutaneous approach has substituted palliative surgery with jejunobiliary anastomosis to manage critical cholangitis or hepatic abscess^{78, 79}. Dilatation of bile duct strictures endoscopically followed by insertion of multiple plastic stents is another alternative to percutaneous interventions as it quickly manages internal bile obstruction⁷⁹. Adjuvant therapy with urso-deoxycholic acid (UDCA) is practiced in few centers; however its efficacy in prophylactic stent obstruction needs approval from prospective studies⁷⁹.

Benefits of interventional procedures:

Interventional procedures in combination with adjuvant chemotherapy may improve the quality and expectancy of life of AE patients⁸⁹.

Risks associated with interventional procedures:

Risks of endoscopic and percutaneous interventions (EPIs) include hemorrhage and internal or prolonged external biliary leakage⁸⁹. The Strength of recommendation and quality of evidence as per IDSA guidelines is B and III respectively⁸⁹.

Surveillance of AE patients:

All types of treatment modalities require regular long-term follow-up by U/S and CT/or MRI scans at interval of 2–3 years. Progress of disease is manifested as enlargement of lesions with passage of time. Serum drug level of ABZ should be determined 4 hours later to morning dose approximately 3 months after treatment initiation and 2–4 weeks after each dose adjustment. The target therapeutic range is 0.65–3 mol/L. If two serial

serum levels of ABZ are > 10 mol/L, then the dose of this drug needs reduction. Similarly, serum MBZ level can also be monitored and it should be > 250 nmol/L⁴⁷. The levels of anti-Em2 and anti-Em18 antibodies fall quickly even up-to extent of non-detection after total surgical excision of lesions⁹³. Serologic tests interpretation in AE patients managed with chemotherapy without radical resection is complex and needs careful interpretation⁹⁶. The detection of anti-Il/3-10/Em18 antibodies favors viable metacestodes of AE and disappearance of these antibodies indicates dying out of these lesions⁹⁷.

Acknowledgement

This manuscript is presented by author as guidelines for Hydatid Liver Disease (HLD) management in 17th Annual Conference of Pakistan Society of Hepatology (PSH 2017), November 3-5, 2017 at Peshawar, Pakistan with the theme of "Challenges in everyday clinical practice" and is also available on PSH website.

REFERENCES

1. Budke CM, Deplazes P, Torgerson PR. Global socioeconomic impact of cystic echinococcosis. *Emerging infectious diseases*. 2006;12(2):296.
2. Torgerson PR, Schweiger A, Deplazes P, Pohar M, Reichen J, Ammann RW, et al. Alveolar echinococcosis: from a deadly disease to a well-controlled infection. Relative survival and economic analysis in Switzerland over the last 35 years. *Journal of hepatology*. 2008;49(1):72-7.
3. Ammann RW, Eckert J. Cestodes. *Gastroenterology Clinics*. 1996;25(3):655-89.
4. Junghanss T, da Silva AM, Horton J, Chiodini PL, Brunetti E. Clinical management of cystic echinococcosis: state of the art, problems, and perspectives. *The American journal of tropical medicine and hygiene*. 2008;79(3):301-11.
5. Kjossev KT, Losanoff JE. Classification of hydatid liver cysts. *Journal of gastroenterology and hepatology*. 2005;20(3):352-9.
6. Larrieu E, Frider B. Human cystic echinococcosis: contributions to the natural history of the disease. *Annals of Tropical Medicine & Parasitology*. 2001;95(7):679-87.
7. McManus DP, Zhang W, Li J, Bartley PB. Echinococcosis. *The Lancet*. 2003;362(9392):1295-304.
8. Yang Y. Hydatidosis and Intervention Strategies. *Current Topics in Echinococcosis: InTech*; 2015.
9. Frider B, Larrieu E, Odriozola M. Long-term outcome of asymptomatic liver hydatidosis. *Journal of Hepatology*. 1999;30(2):228-31.
10. Müfit K, Nejat I, Mercan S, Ibrahim K, Mete UY, Yüksel K. Growth of multiple hydatid cysts evaluated by computed tomography. *Journal of clinical neuroscience*. 1998;5(2):215-7.
11. Yang YR, Sun T, Li Z, Zhang J, Teng J, Liu X, et al. Community surveys and risk factor analysis of human alveolar and cystic echinococcosis in Ningxia Hui Autonomous Region, China. *Bulletin of the World Health Organization*. 2006;84(9):714-21.
12. Rogan MT, Hai WY, Richardson R, Zeyhle E, Craig PS. Hydatid cysts: does every picture tell a story? *Trends in parasitology*. 2006;22(9):431-8.
13. Macpherson CN, Milner R. Performance characteristics and quality control of community based ultrasound surveys for cystic and alveolar echinococcosis. *Acta tropica*. 2003;85(2):203-9.
14. Group WIW. International classification of ultrasound images in cystic echinococcosis for application in clinical and field epidemiological settings. *Acta tropica*. 2003;85(2):253-61.
15. Gharbi HA, Hassine W, Brauner M, Dupuch K. Ultrasound examination of the hydatid liver. *Radiology*. 1981;139(2):459-63.
16. Hosch W, Junghanss T, Stojkovic M, Brunetti E, Heye T, Kauffmann GW, et al. Metabolic viability assessment of cystic echinococcosis using high-field 1H MRS of cyst contents. *NMR in Biomedicine*. 2008;21(7):734-54.
17. Hosch W, Stojkovic M, Jänisch T, Kauffmann GW, Junghanss T. The role of calcification for staging cystic echinococcosis (CE). *European radiology*. 2007;17(10):2538-45.
18. Siracusano A, Bruschi F. Cystic echinococcosis: progress and limits in epidemiology and immunodiagnosis. *Parassitologia*. 2006;48(1-2):65-6.
19. Ito A, Craig PS. Immunodiagnostic and molecular approaches for the detection of taeniid cestode infections. *Trends in parasitology*. 2003;19(9):377-81.
20. Siles-Lucas M, Gottstein B. Molecular tools for the diagnosis of cystic and alveolar echinococcosis. *Tropical Medicine & International Health*. 2001;6(6):463-75.
21. ÇOKER A. The optimal treatment of hydatid cyst of the liver: radical surgery with a significant reduced risk of recurrence. *Turk J Gastroenterol*. 2008;19(1):33-9.
22. Akbulut S, Senol A, Sezgin A, Cakabay B, Dursun M, Satici O. Radical vs conservative surgery for hydatid liver cysts: experience from single center. *World Journal of Gastroenterology: WJG*. 2010;16(8):953.
23. Altinli E, Saribeyoglu K, Pekmezci S, Uras C, Tasçi H, Akçal T. An effective omentoplasty technique in laparoscopic surgery for hydatid disease of the liver. *JSLs: Journal of the Society of Laparoendoscopic Surgeons*. 2002;6(4):323.
24. Isitmangila T, Sebita S, Tunca H, Gorura R, Erdika O, Pocanb S, et al. Clinical experience of surgical therapy in 207 patients with thoracic hydatidosis over a 12-year period. *Methods*. 2001.
25. Baskaran V, Patnaik PK. Feasibility and safety of laparoscopic management of hydatid disease of the liver. *JSLs: Journal of the Society of Laparoendoscopic Surgeons*. 2004;8(4):359.
26. Chowbey P, Shah S, Khullar R, Sharma A, Soni V, Bajjal M, et al. Minimal access surgery for hydatid cyst disease: laparoscopic, thoracoscopic, and

Hydatid Liver Disease.

- retroperitoneoscopic approach. *Journal of Laparoendoscopic & Advanced Surgical Techniques*. 2003;13(3):159-65.
27. Al-Shareef Z, Hamour OA, Al-Shlash S, Ahmed I, Mohamed AA. Laparoscopic treatment of hepatic hydatid cysts with a liposuction device. *JLS: Journal of the Society of Laparoendoscopic Surgeons*. 2002;6(4):327.
28. da Silva AM. Hydatid cyst of the liver—criteria for the selection of appropriate treatment. *Acta tropica*. 2003;85(2):237-42.
29. Peng X, Zhang S, Niu J, Wu X, Pan H, Chen Y. Total subadventitial cystectomy for the treatment of 30 patients with hepatic hydatid cysts. *Chin J Gen Surg*. 2002;17:529-30.
30. Eckert J, Gemmell M, Meslin F-X, Pawlowski Z. WHO-OIE Manual on Echinococcosis in Humans and Animals: A Public Health Problem of Global Concern. World organisation for animal health Paris; 2001.
31. Nour NB, Nunez S, Gianinazzi C, Gorcii M, Müller N, Nouri A, et al. Assessment of Echinococcus granulosus somatic protoscolex antigens for serological follow-up of young patients surgically treated for cystic echinococcosis. *Journal of clinical microbiology*. 2008;46(5):1631-40.
32. Arif SH, Wani NA, Zargar SA, Wani MA, Tabassum R, Hussain Z, et al. Albendazole as an adjuvant to the standard surgical management of hydatid cyst liver. *International Journal of Surgery*. 2008;6(6):448-51.
33. Fenton-Lee D, Morris D. The management of hydatid disease of the liver: Part 2. *Tropical doctor*. 1997;27(2):87-8.
34. Dziri C, Haouet K, Fingerhut A. Treatment of hydatid cyst of the liver: where is the evidence? *World journal of surgery*. 2004;28(8):731-6.
35. Dziri C, Haouet K, Fingerhut A, Zaouche A. Management of cystic echinococcosis complications and dissemination: where is the evidence? *World journal of surgery*. 2009;33(6):1266-73.
36. Haddad MC, Sammak BM, Al-Karawi M. Percutaneous treatment of heterogertous predominantly solid echopattern echinococcal cysts of the liver. *Cardiovascular and interventional radiology*. 2000;23(2):121-5.
37. Smego Jr RA, Bhatti S, Khaliq AA, Beg MA. Percutaneous aspiration-injection-reaspiration drainage plus albendazole or mebendazole for hepatic cystic echinococcosis: a meta-analysis. *Clinical infectious diseases*. 2003;37(8):1073-83.
38. Gargouri M, Amor NB, Chehida FB, Hammou A, Gharbi HA, Cheikh MB, et al. Percutaneous treatment of hydatid cysts (*Echinococcus granulosus*). *Cardiovascular and interventional radiology*. 1990;13(3):169-73.
39. Ustunsoz B, Ugurel MS, Uzar AI, Duru NK. Percutaneous treatment of hepatic hydatid cyst in pregnancy: long-term results. *Archives of gynecology and obstetrics*. 2008;277(6):547-50.
40. Khuroo MS, Wani NA, Javid G, Khan BA, Yattoo GN, Shah AH, et al. Percutaneous drainage compared with surgery for hepatic hydatid cysts. *New England Journal of Medicine*. 1997;337(13):881-7.
41. Acunas B, Rozanes I, Celik L, Minareci O, Acunas G, Alper A, et al. Purely cystic hydatid disease of the liver: treatment with percutaneous aspiration and injection of hypertonic saline. *Radiology*. 1992;182(2):541-3.
42. Khuroo MS, Dar MY, Yattoo GN, Zargar SA, Javaid G, Khan BA, et al. Percutaneous drainage versus albendazole therapy in hepatic hydatidosis: a prospective, randomized study. *Gastroenterology*. 1993;104(5):1452-9.
43. Erzurumlu K, Şahin M, Selcuk M, Yildiz C, Kesim M. Intracystic application of mebendazole solution in the treatment of liver hydatid disease. *European surgical research*. 1996;28(6):466-70.
44. Giorgio A, Tarantino L, Francica G, Mariniello N, Aloisio T, Soscia E, et al. Unilocular hydatid liver cysts: treatment with US-guided, double percutaneous aspiration and alcohol injection. *Radiology*. 1992;184(3):705-10.
45. Bastid C, Azar C, Doyer M, Sahel J. Percutaneous treatment of hydatid cysts under sonographic guidance. *Digestive diseases and sciences*. 1994;39(7):1576-80.
46. Akhan O, Ozmen MN, Dincer A, Sayek I, Göçmen A. Liver hydatid disease: long-term results of percutaneous treatment. *Radiology*. 1996;198(1):259-64.
47. Brunetti E, Kern P, Vuitton DA. Expert consensus for the diagnosis and treatment of cystic and alveolar echinococcosis in humans. *Acta tropica*. 2010;114(1):1-16.
48. Morris D, Taylor D. Optimal timing of post-operative albendazole prophylaxis in *E. granulosus*. *Annals of Tropical Medicine & Parasitology*. 1988;82(1):65-6.
49. Filice C, Brunetti E. Use of PAIR in human cystic echinococcosis. *Acta Tropica*. 1997;64(1):95-107.
50. Men S, Yücesoy C, Edgüer T, Hekimoğlu B. Percutaneous treatment of giant abdominal hydatid cysts: long-term results. *Surgical Endoscopy And Other Interventional Techniques*. 2006;20(10):1600-6.
51. Ustünsöz B, Akhan O, Kamiloğlu M, Somuncu I, Uğurel M, Cetiner S. Percutaneous treatment of hydatid cysts of the liver: long-term results. *AJR American journal of roentgenology*. 1999;172(1):91-6.
52. Yaghan R, Heis H, Bani-Hani K, Matalka I, Shatanawi N, Gharaibeh K, et al. Is fear of anaphylactic shock discouraging surgeons from more widely adopting percutaneous and laparoscopic techniques in the treatment of liver hydatid cyst? *The American journal of surgery*. 2004;187(4):533-7.
53. Sayek I, Tirnaksiz MB, Dogan R. Cystic hydatid disease: current trends in diagnosis and management. *Surgery today*. 2004;34(12):987-96.
54. Schipper H, Lameris J, Van Delden O, Rauws E, Kager P. Percutaneous evacuation (PEVAC) of multivesicular echinococcal cysts with or without cystobiliary fistulas which contain non-drainable material: first results of a modified PAIR method. *Gut*. 2002;50(5):718-23.

Hydatid Liver Disease.

55. Saremi F, McNamara T. Hydatid cysts of the liver: long-term results of percutaneous treatment using a cutting instrument. *AJR American journal of roentgenology*. 1995;165(5):1163-7.
56. Bartholomot G, Vuitton DA, Harraga S, Giraudoux P, Barnish G, Wang YH, et al. Combined ultrasound and serologic screening for hepatic alveolar echinococcosis in central China. *The American journal of tropical medicine and hygiene*. 2002;66(1):23-9.
57. Akhan O, Gumus B, Akinci D, Karcaaltincaba M, Ozmen M. Diagnosis and percutaneous treatment of soft-tissue hydatid cysts. *Cardiovascular and interventional radiology*. 2007;30(3):419-25.
58. Cobo F, Yarnoz C, Sesma B, Fraile P, Aizcorbe M, Trujillo R, et al. Albendazole plus praziquantel versus albendazole alone as a pre-operative treatment in intra-abdominal hydatidosis caused by *Echinococcus granulosus*. *Tropical Medicine and International Health*. 1998;3(6):462-6.
59. Bradley M, Horton J. Assessing the risk of benzimidazole therapy during pregnancy. *Transactions of the Royal Society of Tropical Medicine and Hygiene*. 2001;95(1):72-3.
60. Franchi C, Di Vico B, Teggi A. Long-term evaluation of patients with hydatidosis treated with benzimidazole carbamates. *Clinical Infectious Diseases*. 1999;29(2):304-9.
61. Doğru D, Kiper N, Özçelik U, Yalçın E, Göçmen A. Medical treatment of pulmonary hydatid disease: for which child? *Parasitology international*. 2005;54(2):135-8.
62. Marchetti S, Mazzanti R, Beijnen JH, Schellens JH. Concise review: clinical relevance of drug–drug and herb–drug interactions mediated by the ABC transporter ABCB1 (MDR1, P-glycoprotein). *The oncologist*. 2007;12(8):927-41.
63. Bygott J, Chiodini P. Praziquantel: neglected drug? Ineffective treatment? Or therapeutic choice in cystic hydatid disease? *Acta tropica*. 2009;111(2):95-101.
64. Marchiondo AA, Ming R, Andersen FL, Slusser JH, Conder GA. Enhanced larval cyst growth of *Echinococcus multilocularis* in praziquantel-treated jirds (*Meriones unguiculatus*). *The American journal of tropical medicine and hygiene*. 1994;50(1):120-7.
65. Vutova K, Mechkov G, Vachkov P, Petkov R, Georgiev P, Handjiev S, et al. Effect of mebendazole on human cystic echinococcosis: the role of dosage and treatment duration. *Annals of Tropical Medicine & Parasitology*. 1999;93(4):357-65.
66. Stojkovic M, Zwahlen M, Teggi A, Vutova K, Cretu CM, Virdone R, et al. Treatment response of cystic echinococcosis to benzimidazoles: a systematic review. *PLoS neglected tropical diseases*. 2009;3(9):e524.
67. Craig PS, Budke CM, Schantz PM, Li T, Qiu J, Yang Y, et al. Human echinococcosis: a neglected disease? *Tropical Medicine and Health*. 2007;35(4):283-92.
68. Lanchote VL, Garcia FS, Dreossi SA, Takayanagui OM. Pharmacokinetic interaction between albendazole sulfoxide enantiomers and antiepileptic drugs in patients with neurocysticercosis. *Therapeutic drug monitoring*. 2002;24(3):338-45.
69. Chawla A, Maheshwari M, Parmar H, Hira P, Hanchate V. Imaging features of disseminated peritoneal hydatidosis before and after medical treatment. *Clinical radiology*. 2003;58(10):818-20.
70. Kish MA. Guide to development of practice guidelines. *Clinical Infectious Diseases*. 2001;32(6):851-4.
71. Bresson-Hadni S, Laplante J-J, Lenys D, Rohmer P, Gottstein B, Jacquier P, et al. Seroepidemiologic screening of *Echinococcus multilocularis* infection in a European area endemic for alveolar echinococcosis. *The American journal of tropical medicine and hygiene*. 1994;51(6):837-46.
72. Kadry Z, Renner E, Bachmann L, Attigah N, Renner E, Ammann R, et al. Evaluation of treatment and long-term follow-up in patients with hepatic alveolar echinococcosis. *British Journal of Surgery*. 2005;92(9):1110-6.
73. Kern P, Bardonnnet K, Renner E, Auer H, Pawlowski Z, Ammann RW, et al. European echinococcosis registry: human alveolar echinococcosis, Europe, 1982–2000. *Emerging infectious diseases*. 2003;9(3):343.
74. Akarsu M, Kantar FU, Gülcü A. *Echinococcosis*. *Zoonosis: InTech*; 2012.
75. Romig T, Kratzer W, Kimmig P, Frosch M, Gaus W, Flegel WA, et al. An epidemiologic survey of human alveolar echinococcosis in southwestern Germany. Römerstein Study Group. *The American journal of tropical medicine and hygiene*. 1999;61(4):566-73.
76. Rausch R, Wilson J, Schantz P, McMahon B. Spontaneous death of *Echinococcus multilocularis*: cases diagnosed serologically (by Em2 ELISA) and clinical significance. *The American journal of tropical medicine and hygiene*. 1987;36(3):576-85.
77. Gottstein B, Saucy F, Deplazes P, Reichen J, Dummer G, Busato A, et al. Is high prevalence of *Echinococcus multilocularis* in wild and domestic animals associated with disease incidence in humans? *Emerging infectious diseases*. 2001;7(3):408.
78. Bresson-Hadni S, Vuitton D-A, Bartholomot B, Heyd B, Godart D, Meyer J-P, et al. A twenty-year history of alveolar echinococcosis: analysis of a series of 117 patients from eastern France. *European journal of gastroenterology & hepatology*. 2000;12(3):327-34.
79. Bresson-Hadni S, Delabrousse E, Blagosklonov O, Bartholomot B, Koch S, Miguet J-P, et al. Imaging aspects and non-surgical interventional treatment in human alveolar echinococcosis. *Parasitology international*. 2006;55:S267-S72.
80. Craig P. *Echinococcus multilocularis*. *Current opinion in infectious diseases*. 2003;16(5):437-44.
81. Xiao N, Mamuti W, Yamasaki H, Sako Y, Nakao M, Nakaya K, et al. Evaluation of use of recombinant Em18 and affinity-purified Em18 for serological differentiation of alveolar echinococcosis from cystic echinococcosis and other parasitic infections. *Journal of clinical microbiology*. 2003;41(7):3351-3.
82. Stumpe K, Renner-Schneiter E, Kuenzle A, Grimm F, Kadry Z, Clavien P-A, et al. F-18-fluorodeoxyglucose

Hydatid Liver Disease.

- (FDG) positron-emission tomography of Echinococcus multilocularis liver lesions: prospective evaluation of its value for diagnosis and follow-up during benzimidazole therapy. *Infection*. 2007;35(1):11-8.
83. Reuter S, Buck A, Manfras B, Kratzer W, Seitz HM, Darge K, et al. Structured treatment interruption in patients with alveolar echinococcosis. *Hepatology*. 2004;39(2):509-17.
84. Kern P, Wen H, Sato N, Vuitton DA, Gruener B, Shao Y, et al. WHO classification of alveolar echinococcosis: principles and application. *Parasitology International*. 2006;55:S283-S7.
85. Buttenschoen K, Buttenschoen DC, Gruener B, Kern P, Beger HG, Henne-Bruns D, et al. Long-term experience on surgical treatment of alveolar echinococcosis. *Langenbeck's archives of surgery*. 2009;394(4):689.
86. Reuter S, Jensen B, Buttenschoen K, Kratzer W, Kern P. Benzimidazoles in the treatment of alveolar echinococcosis: a comparative study and review of the literature. *Journal of Antimicrobial Chemotherapy*. 2000;46(3):451-6.
87. Ishizu H, Uchino J, Sato N, Aoki S, Suzuki K, Kuriyashi H. Effect of albendazole on recurrent and residual alveolar echinococcosis of the liver after surgery. *Hepatology*. 1997;25(3):528-31.
88. Ito A, Nakao M, Kutsumi H, Lightowlers MW, Itoh M, Sato S. Serodiagnosis of alveolar hydatid disease by Western blotting. *Transactions of the Royal Society of Tropical Medicine and Hygiene*. 1993;87(2):170-2.
89. Buttenschoen K, Gruener B, Buttenschoen DC, Reuter S, Henne-Bruns D, Kern P. Palliative operation for the treatment of alveolar echinococcosis. *Langenbeck's archives of surgery*. 2009;394(1):199.
90. Koch S, Bresson-Hadni S, Miguet J-P, Crumbach J-P, Gillet M, Mantion G-A, et al. Experience of liver transplantation for incurable alveolar echinococcosis: a 45-case European collaborative report. *Transplantation*. 2003;75(6):856-63.
91. Bresson-Hadni S, Koch S, Miguet J-P, Gillet M, Mantion G-A, Heyd B, et al. Indications and results of liver transplantation for Echinococcus alveolar infection: an overview. *Langenbeck's archives of surgery*. 2003;388(4):231-8.
92. Vuitton D, Zhou H, Bresson-Hadni S, Wang Q, Piarroux M, Raoul F, et al. Epidemiology of alveolar echinococcosis with particular reference to China and Europe. *Parasitology*. 2003;127(S1):S87-S107.
93. Scheuring UJ, Seitz HM, Wellmann A, Hartlapp JH, Tappe D, Brehm K, et al. Long-term benzimidazole treatment of alveolar echinococcosis with hematogenic subcutaneous and bone dissemination. *Medical microbiology and immunology*. 2003;192(4):193-5.
94. Reuter S, Buck A, Grebe O, Nüsse-Kügele K, Kern P, Manfras BJ. Salvage treatment with amphotericin B in progressive human alveolar echinococcosis. *Antimicrobial agents and chemotherapy*. 2003;47(11):3586-91.
95. Kern P, Abboud P, Kern WV, Stich A, Bresson-Hadni S, Guerin B, et al., editors. Critical appraisal of nitazoxanide for the treatment of alveolar echinococcosis. *American Journal of Tropical Medicine and Hygiene*; 2008: AMER SOC TROP MED & HYGIENE 8000 WESTPARK DR, STE 130, MCLEAN, VA 22101 USA.
96. Tappe D, Frosch M, Sako Y, Itoh S, Grüner B, Reuter S, et al. Close relationship between clinical regression and specific serology in the follow-up of patients with alveolar echinococcosis in different clinical stages. *The American journal of tropical medicine and hygiene*. 2009;80(5):792-7.
97. Ammann RW, Renner EC, Gottstein B, Grimm F, Eckert J, Renner EL, et al. Immunosurveillance of alveolar echinococcosis by specific humoral and cellular immune tests: long-term analysis of the Swiss chemotherapy trial (1976–2001). *Journal of hepatology*. 2004;41(4):551-9.

CONFLICT OF INTEREST: Authors declare no conflict of interest

GRANT SUPPORT AND FINANCIAL DISCLOSURE NIL

AUTHOR'S CONTRIBUTION

Following authors have made substantial contributions to the manuscript as under:

- Haider I:** Main idea, Literature and systemic review, article writing.
- Humayun M:** Supervision and conceptualization of draft.
- Badshah A:** Literature Search, final draft, proof reading.
- Khan ZU:** Data analysis, article writing and formatting.
- Bangash M:** Data compilation, proof reading.

Authors agree to be accountable for all aspects of the work in ensuring that questions related to the accuracy or integrity of any part of the work are appropriately investigated and resolved.