

CASE REPORT

SPONTANEOUS CARDIAC RUPTURE IN A 45 YEARS OLD MALE: AUTOPSY, MICROSCOPIC & LABORATORY FINDINGS

Mian Saad Ahmed¹, Naila Ismail², Ijaz Aziz¹, Hakim Khan Afridi¹

¹Department of Forensic Medicine Khyber Medical College, Peshawar - Pakistan

²Department of Pathology Khyber Medical College, Peshawar - Pakistan

ABSTRACT

Cardiac rupture is among one of the most common cause of sudden death after acute Myocardial Infarction (MI) and can also be due to trauma and other iatrogenic causes. A 45 years old male brought dead in the autopsy room of department of Forensic Medicine Khyber Medical College, to determine the cause of sudden death. The deceased having strong family history of ischemic heart disease, hypertension & cerebrovascular accident/strokes, went through coronary artery bypass graft post inferoposterior MI six years ago and had a 12 year of hypertensive history at time of death. Because of which fibrotic and hypertrophied changes were found in the left/right ventricular walls. In autopsy findings hemopericardium with rupture myocardium was noted where as microscopy revealed fibrosis, coronary blockage, calcification and neutrophilic infiltration. The laboratory results for detection of proteins is also positive for Troponin T. Cardiac rupture itself is not a one day process, a number contributory factors like hypertension, previous ischemic heart disease, age, thrombolytic/antiplatelet drugs etc are involved in it. Preventive measures of modifiable risk factors and regular checkups among the suspected can play a key role.

Key Words: Heart Rupture, Microscopy, Autopsy

Abbreviations:

IHD	=	Ischemic heart disease
CABG	=	Coronary artery bypass graft
MI	=	Myocardial Infarction
HTN	=	Hypertension
CVA	=	Cerebrovascular Accident
TVD	=	Triple vessel disease

This article may be cited as: Ahmed MS, Ismail N, Aziz I, Afridi HK. Spontaneous cardiac rupture in a 45 years old male: autopsy, microscopic & laboratory findings. J Med Sci 2017; 25: (2) ??-//.

INTRODUCTION

Sudden natural death, a condition in which a person dies within 24 hours after the start of a disease or terminal event and the person does not have any serious disease, injury or poisoning.¹ Cardiovascular causes are among the most common causes of sudden death ranging from 45-50%.² Rupture of ventricle is a

rare and fatal complication of acute Myocardial Infarction, it is second leading cause of in hospital deaths and responsible for 15% of death.³ Free wall of left ventricle is a region which is not in continuation with the septum of interventricular region. Myocardial ruptures were first diagnosed by William Harvey in 1647.

Case Report Information

A 45 Years old subject with history of coronary artery bypass graft surgery (CABG) in March 2009 post inferoposterior Myocardial Infarction (MI) Jan 2009 was brought dead to the Autopsy room of department of Forensic Medicine Khyber Medical College, Peshawar with inquest of Police for post mortem as it was a case of sudden death.

Mian Saad Ahmed (Corresponding Author)

Demonstrator

Department of Forensic Medicine, Khyber Medical College - Peshawar

Cell: +92-333-9867700

Email: saadahmedmian@gmail.com

Date Received: 09 November 2016

Date Revised: 09 December 2016

Date Accepted: 09 January 2017

History (Family, Past, Clinical & Incident of Death)

The subject had strongly positive family history of ischemic heart diseases (IHD), hypertension (HTN) and ischemic and hemorrhagic stroke. He was having 6 years of hypertension when in Jan 2009 inferoposterior Myocardial Infarction (MI) was diagnosed, post MI echocardiography showed inferoposterior akinetic changes which was further led to the diagnosis of triple vessel disease (TVD) in angiography Feb 2009. The subject was operated for TVD by operation named coronary artery bypass graft (CABG) surgery in March 2009 and was on medication since then till the incident. It was reported that subject felt extremely heavy stabbing parasternal pain before falling down on ground and got fainted, he died in minutes even wasn't able to reach the hospital.

Autopsy Findings

A middle aged, average built male wearing blue color dress was brought to the autopsy room. Upon external examination rigor mortis started to develop, pupil was dilated and fixed with hazy cornea while no injury, bruise and sign of physical assault was found on the body. In internal examination as the chest was opened and sternum was removed, pericardial sac full of blood was visible. Fresh and clotted blood of more than 1 liter amount was covering the whole heart. On removal of blood and separation of pericardium rupture heart (15*15*8cm) was identified. The heart was dissected carefully and hypertrophied ventricle with atheroma (whitish grayish spots) were found in ventricles, atriums and inter-ventricular septum. Rupture heart is shown in Fig: 1

Microscopic Findings

Slides of different section of subjects heart were prepared by Department of Pathology Khyber Medical College, Peshawar clearly suggestive of recent infarction and old ischemic changes and occlusive vascular diseases. Fig: 2 showing left ventricular calcification with neutrophilic infiltration. Fig: 3 (A) shows complete blockage of coronary vessels suggestive of ischemia and myocardial infarction, 3 (B) shows massive fibrosis in left ventricular wall suggestive of hypertrophy and damaged cardiac myocytes easily liable to rupture.

Laboratory Findings

Blood of the subject was sent to laboratory for the protein detection of Troponin T, which was strongly positive on strip method suggestive of intense cardiac muscle damage.

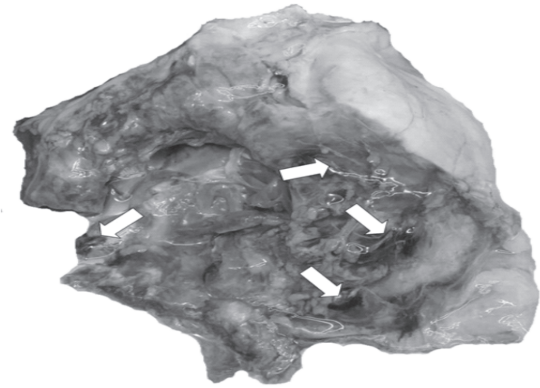


Fig 1: Sites showing rupture of Heart (Myocardium)

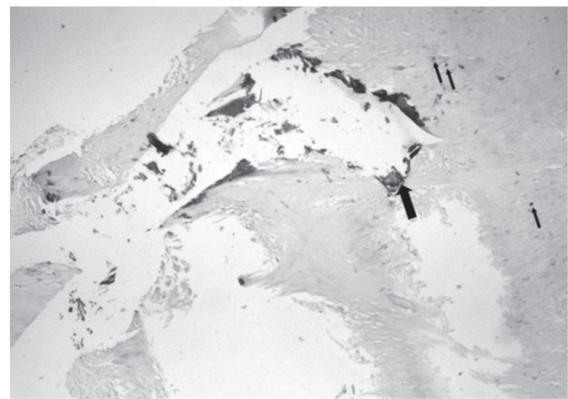


Fig 2: Calcification and Neutrophilic infiltration (Left Ventricle)

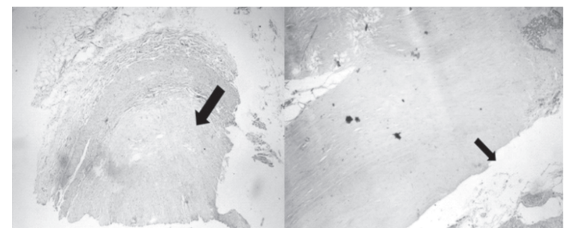


Fig 3: Complete coronary artery blockage (A) & Massive Fibrosis (B)

DISCUSSION

Myocardial rupture is one of the early complication of Acute Myocardial Infarction with peak of incidence (within 24 hours and 3-5 days), also by 1-14 days, it may present as many forms of rupture.⁴ Cardiac rupture occurs in various iatrogenic, traumatic (penetrating, blunt etc) and non traumatic conditions (infection, tumors, fatty infiltration and infiltrative diseases etc).⁵ The clinical outcomes of this pathology includes sudden severe cardiac tamponade followed by rapid death, sub-acute rupture and formation of pseudo-aneurysm.⁶

Generally cardiac rupture presents with persistent

protracted/stabbing para-sternal chest pain, restlessness, emesis and agitation followed by sudden death that is consistent with presentations of above mentioned subject. It is being estimated that about 1/3rd patients with cardiac rupture after MI may have subacute rupture with less severe tamponade presenting with hemodynamic instability, that must be treated immediately for positive results.⁷ At some instances, it may take 3-5 days after infarct, however most of the post mortem studies have shown cardiac rupture within 72 hours.⁸ Studies shows antiplatelets therapy used in reducing mortality due to MI, increases the chances for cardiac rupture within 48 hours, as found in the above subject who used antiplatelets for 15 years till death. However few non symptomatic cases with cardiac rupture have also been reported.⁹ Contributory factors in cardiac ruptures similar with the subject above are HTN, old MI, hypertrophy/fibrosis of left/right ventricles and neutrophilic infiltration. Rupture site of the heart is mostly dilated due to ischemia, which is ventricular apex, ventricular free wall and interventricular septum as reported and documented in this case.¹⁰

Histopathological findings of calcification, fibrosis revealed old infarction where as neutrophilic infiltration is the evidence of recent ongoing infarction making the free wall of ventricles weak and more prone to rupture. Myocardial infarction being irreversible necrotic activity that can be diagnosed by protein detection in the blood, in a study by Sharma D et al 65-100% of cases had positive trop t between 0-12hrs.

CONCLUSION

This case will enlighten the autopsy experts in identifying the cause of sudden death in middle aged people. Old IHD, HTN, CVA/Stroke, antiplatelets drugs therapy remains to be contributory factors of cardiac ruptures, for which regular checkup and modification in lifestyle is mandatory.

REFERENCES

1. Reddy KSN. The essentials of Forensic Medicine and Toxicology. 32nd ed. Hyderabad: K.Suguna Devi;2013.Chapter 6,Death and its cause;p.130-45.
2. Mukherjee JB. Injury and its Medico-legal aspects 2007, 3rd ed, Karmakar R.N., Academic publisher, p226-228.
3. Davis N, Sistino JJ. Review of ventricular rupture: key concepts and diagnostic tools for success. *Perfusion* 2002;17:63-7.
4. Antman EM et al. Myocardial infarction: Management in Braunwald's Heart Disease, 9th Ed, RO Bonow et al. (eds.), Elsevier Saunders, 2012, 1146-1148
5. Gabriele AK, Maythem S, Charles BH. Cardiac Masses. In Charles BH, Albert R, editors. MRI and CT of the Cardiovascular System. 2nd Ed Philadelphia:Lippincott Williamsand Wilkins 2006
6. Yeo TC, Malouf JF, Oh JK, et al. Clinical profile and outcome in 52 patients with cardiac pseudoaneurysm. *Ann Intern Med* 1998;128:299 - 305.
7. Lopez-Sendon J, Gonzalez A, Lopez de SA E, et al. Diagnosis of subacute ventricular wall rupture after acute myocardial infarction: sensitivity and specificity of clinical, hemodynamic and echocardiographic criteria. *J Am Coll Cardiol* 1992;19:1145-53.
8. Bonello L, Theron A, Lambert M, et al. Cardiac rupture or pericardial effusion? *Int J Cardiol* 2008;127:142-4
9. The Fibrinolytic Therapy Trialists Collaboration. Indications for fibrinolytic therapy in suspected acute myocardial infarction: collaborative overview of early mortality and major morbidity results from all randomized trials of more than 1000 patients. *Lancet* 1994;343:311-22.
10. Sharma D, Gupta P, Srivastava S, Jain H. Sensitivity and specificity of cardiac troponin-T in diagnosis of acute myocardial infarction: *Int J Adv Med.* 2017 Feb;4(1):244-46