

IS LAPAROSCOPIC EXPLORATION AN IDEAL APPROACH TO TREAT IMPALPABLE TESTIS? A SINGLE CENTRE EXPERIENCE

Fayaz Ur Rahman, Inayat Ur Rehman, Waheed Akhtar

Department of Paediatric Surgery, Khyber Teaching Hospital, Peshawar - Pakistan

ABSTRACT

Objective: To share our experience of management of Impalpable testis (IPT) by laparoscopic exploration and call attention to its importance.

Material and Methods: This prospective observational study was conducted at paediatric surgery unit, Khyber Teaching Hospital Peshawar-Pakistan, from July 2015 to January 2017. All patients labelled as non-palpable testis (IPT) on clinical examination were subjected to Ultrasound for further confirmation. Laparoscopic exploration was done for all patients IPT. Single stage orchidopexy done for low IPT and two stage orchidopexy done for high IPT. Inguinal exploration was performed in cases where vas & vessels were found exiting the deep ring.

Results: laparoscopic exploration was done for 62 IPT testis on 40 patients with a mean age of presentation 4.62 ± 2.83 years (max of 13 years and min 1 years). Patients with bilateral IPT 55% (22 out of 40) and unilateral IPT 45% (18 out of 40). IPT on right side 55.5% (10 out of 18) and IPT on left side 44.5% (8 out of 18). Operative finding revealed 79% patients having visible intraabdominal testis and 21% patients no testis found on laparoscopy. Visible intraabdominal testis further analysed and showed 63.3% (31/49) truly intrabdominal testis, 28.6% (14/49) peeping testis, 8.1% (4/49) canalicular testis. 13 cases in which no intrabdominal testis were found showed blind ended vas 15.4% (2/13) and vas & vessels exiting the deep ring 84.6% (11/13). Single stage orchidopexy performed in 61.3% (38/62), 2 stage Stephen fowler orchidopexy (SFO) in 17.7% (11/62), laparoscopy followed by exploration in 21% (13/62). After six months follow up, 34.6% (18/52) testis found in good scrotal position, 29% (15/52) in mid scrotal position, 23% base of the penis (12/52), 13.4% (7/52) atrophy.

Conclusion: Laparoscopic treatment of non palpable testis is safe and effective for all types of impalpable testis with the advantage of diagnostic as well as therapeutic.

Keywords: undescended testis, laparoscopy, orchidopexy.

This article may be cited as: Rahman FU, Rahman I, Imran M, Akhtar W. Is laparoscopic exploration an ideal approach to treat impalpable testis? A single centre experience. *J Med Sci* 2019; 27: (1) 11-15.

INTRODUCTION

Undescended testis is one the common condition with incidence of 1% at birth and 0.8% at one year. 20% of undescended testis are clinically impalpable testis (IPT)¹. There is spontaneous descent of testis up to 3 month of age and this is the reason for decrease in incidence to 1-2%. Routine Physical examination of

boys is required after birth for early diagnosing the UDT and this should continue after 3 months. Orchidopexy is recommended after six months of age and before the 2nd birthday of the child. IPT is a diagnostic dilemma and no single radiological investigation is considered best in detecting its position. Previously inguinal exploration was consider best choice to treat IPT. But with introduction of laparoscopy in its treatment resulted to set up a new question of choosing the best choice to treat IPT. Laparoscopic exploration not only allows to determine the presence and position of testis but also provide opportunity for its correction in single or stage procedure^{2,3}. But the role of laparoscopy in treating IPT is still contravesrial and no clear directions are there to

Dr. Fayaz Ur Rahman (Corresponding Author)
Assistant Professor
Department of Pediatric Surgery, Khyber Teaching Hospital, Peshawar - Pakistan
E-mail: fayaz621@gmail.com
Contact: +92 - 313-9857982

Date Received: 29 September 2018
Date Revised: 5 January 2019
Date Accepted: 20 January 2019

support the laparoscopic approach over inguinal exploration⁴. Due to lack of satisfactory guideline in literature for treatment of IPT, we collected data of our patients with IPT, who underwent laparoscopic exploration for it and conducted this study to share our experience of laparoscopic management of IPT.

MATERIAL AND METHODS

All patients with IPT and who underwent laparoscopic exploration for it from July 2015 to January 2017 were included in the study. Patient having non palpable undescended testis and age ranges from 0.8 to 16 years were included in the study. Patients having palpable undescended testis and age less than 6 months were excluded. Record of patient reviewed regarding age of presentation, laterality, side, operative finding, procedure performed, post operative location of the testis in the scrotum. IPT was defined as testis that can't be palpated awake or under general anaesthesia and not detected on inguinal ultrasonography. After laparoscopy IPT can further be categorised as truly intrabdominal testis when located near the iliac vessels, peeping testis is when located near the deep ring, canalicular testis is when Vas and vessels entering the deep ring, absent testis. Single stage orchidopexy performed for canalicular testis, peeping testis and some percentage of high testis with mobilised vessels.

Two stage laparoscopic orchidopexy performed for high intrabdominal testis having short testicular vessels. Patients are followed up done for a period of 6 months with 4 visits on a different interval to the outpatient department. All procedure done under endotracheal general anaesthesia with the patient in supine position and head end down. NG tube passed and urinary catheterization done in all patients. All surgeries performed by the same group of surgeons within a same unit. During follow up testicular size and position in the scrotum recorded on examination. In case of doubt on testicular size Doppler ultrasound done to clear the status of testis. The collected data were revised, tabulated, coded and fed in PC having statistical analysis program SPSS-20. Data was presented and suitable analysis was carried out according to the type of data. Mean and standard deviation was calculated for numerical data. Frequency and percentage for categorical data.

Operative technique of single stage and two

stage SFO Laparoscopy was performed first to confirm the location of testis. A 3.3 mm supraumbilical port fashioned with a closed vareese needle technique and 30 degree telescope to used to determine the location of testis. If vas and vessels found exiting the deep ring then inguinal exploration was performed in search of IPT and if a blind ended vas found then surgery is ended as vanishing testis. In case of intrabdominal testis the procedure was futher accomplished with two more working ports of 3mm in midclavicular line at level of umbilicus. Canalicular and peeping testis can be easily mobilized with a hook cautry and laparoscopic orchidopexy easily completed. Some percentage of high intrabdominal testis near the iliac vessels can be brought down under tension with a risk of injury to the testicular vessels.

Two stage SFO performed on testis located high in abdomen with very short testicular vessels. The operating surgeon decides the stage procedure depending location and vessels length. The testicular vessels clipped with a haemolock using 3mm applicator. Minimal dissection is done in stage procedure. Patients were booked for second stage surgery after 6 months. During second stage same three port technique is performed. Collateral blood vessel identified near the vas to conform the blood supply to the testis. After holding gubernaculum with a grasper, hook cautry used to mobilize the testis. strip of peritoneum is taken with vas to avoid damage to the collateral blood supply. Adequacy of mobilization is confirmed by moving the testis to the contralateral ring. After creating a dartos pouch, testis is brought down to the scrotal sac using Prentiss manuoer (bringing testis straight down with a new rout medial to epigastric vessels). Care is taken to avoid any twist in testis and orchidopexy performed.

RESULTS

Laparoscopic exploration done for 62 impalpable testis on 40 patients. Mean age of patients was 4.62 ± 2.83 years. Age distribution of patients is shown in Fig 1. Bilateral IPT was found in 55% (22 out of 40) while unilateral IPT in 45% (18 out of 40) cases. Unilateral IPT further analysis showed 55.5% (10 out of 18) on the right side and 44.5% (8 out of 18) on left side. Laparoscopic exploration performed in all cases of IPT. Operative finding showed that 79% (49 out of 62) patients had visible intrabdominal testis on laprosocpy

Is laparoscopic exploration an ideal approach to treat impalpable testis? A single centre experience

while in 21% (13 out of 62) patients no intrabdominal testis were found.

Visible intrabdominal testis were further analysed with the finding of truly intrabdominal testis in 63.3% (31 out of 49), peeping testis in 28.5% (14 out of 49) and canalicular testis in 8.1% (4 out of 49). Intrabdominal testis was not palpable in 13 cases, 15.4% (2 out of 13) of which had blind ended Vas inside the peritoneal cavity and 84.6% (11 out of 13) Vas & vessel exiting the deep ring. Inguinal exploration was performed in 11 cases with Vas & vessels exiting the deep ring. 27.3% (3 out of 11) cases Testis were located and orchidopexy performed while in remaining 72.7% (8 out of 11) labelled as vanishing testis.

Single stage orchidopexy performed in 61.3% (38 out of 62) while 2 stage Stephen fowler procedure done

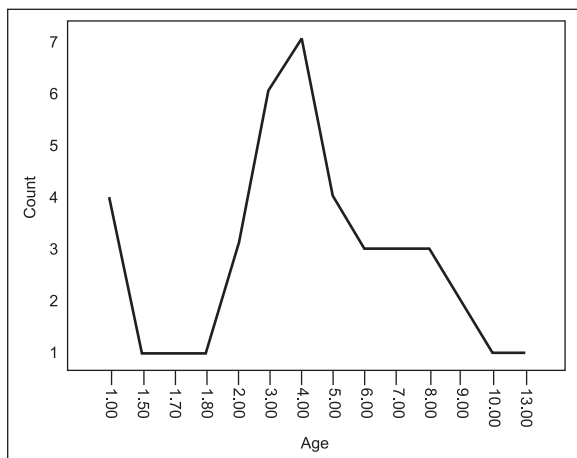


Fig 1: Impalpable testis age distribution

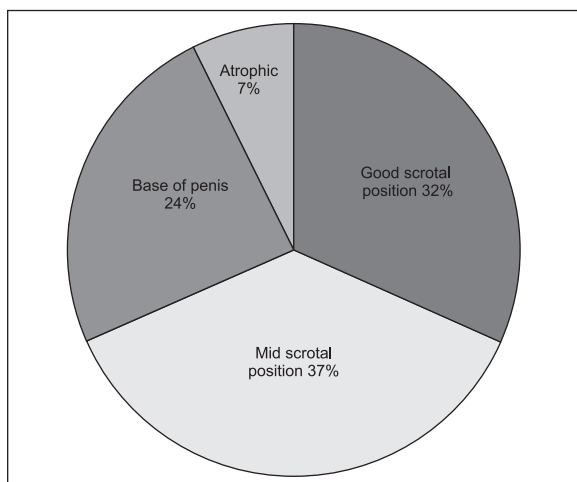


Fig 2: Outcome of laparoscopic orchidopexy for impalpable testis

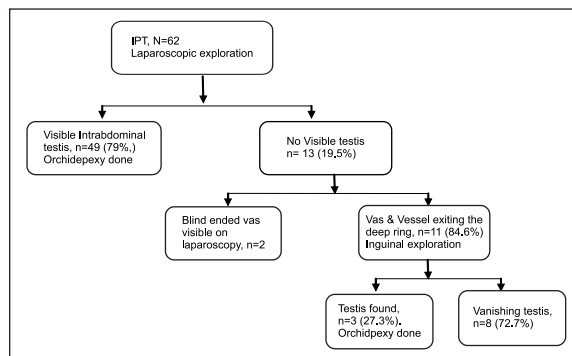


Fig 3: Results of laparoscopic exploration of 62 impalpable testis

in 17.7% (11 out of 62) cases. laparoscopic followed by inguinal exploration was done in 21% (13 out of 62) cases. Outcome of surgery was noted in follow up period and shown in fig 2.

DISCUSSION

Management of impalpable testis is challenging and debate exist concerning initial surgical approach⁵. Literature review clarified that till yet no “gold standard” approach has been defined for treatment of IPT and controversy exists which approach should pave the way to the other, inguinal or laparoscopic. Inguinal exploration as initial surgical approach for IPT was believed to be ineffective, has recently gained popularity. Many authors have found it as safe and reliable for treating IPT^{6,7}. The opponent of this approach believes that only a low percentage of IPT requires two stage laparoscopic procedure by ligating vessels^{8,9}.

Proponent of this approach have the plea that laparoscopy has the extra advantage of locating the testis and has the beauty of natural extension to therapeutic procedure as well^{4,10}. Laparoscopic exploration has the further advantages of early recovery, low pain, excellent visualization and high success rate. We consider laparoscopic exploration as an initial standard approach to IPT as only a small percentage of our patients required inguinal exploration. Inguinal exploration was performed for those cases of absent intrabdominal testis in which vas & vessels exiting the deep ring. Undescended testis require treatment between 6 months and 2 years of age to avoid complications. Delayed presentation is reported in developing countries and this is labelled as important indicator of poor health system^{11,12}. Current study showed mean age 4.5 years. Laparoscopic ex-

ploration can be safely performed for IPT in any group of children.

Laparoscopic management of IPT is reported safe and effective technique with good outcome^{8,13}. Laparoscopic orchidopexy can be a single stage or 2 stage procedure. We performed single stage orchidopexy for all canalicular testis, peeping testis and most of the high intrabdominal testis. For two stage procedure we recommend three indications (1) Testis located more than 2.5 cm above the deep ring (2) age of the patient more than 7 years (3) laxness of testicular vessels. Laparoscopic single stage and two stage orchidopexy has been reported to have the same result, however, the good scrotal position can be achieved only 2 stage procedure^{2,14-16}. Our results revealed good result with a maximum number(69%) of testis located in good and mid scrotal position after 1 years follow up. However, this study has the limitation in comparing the outcome of the two procedures.

In the current study, 19.5% cases revealed no intrabdominal testis and inguinal exploration was decided only for those cases in which Vas & vessel were found exiting the deep ring. No single radiological investigation is best to locate IPT. Most of the time no testis was found on inguinal exploration^{17,18}. In our series such exploration was done for 11 IPT. Only three cases testis were found on exploration and orchidopexy performed. In these 3 cases the ultrasound was not able to locate the testis. We support inguinal exploration for such cases with the idea to reach the final diagnosis before labeling the patient as vanishing testis. Vanishing testis has the reported incidence of 35% to 60% of the IPT and results of antenatal, perinatal vascular insult¹⁹. Evidence support the excision of vanishing testis due to risk malignancy in future²⁰. Current study shows only 10 cases (16%) of vanishing testis.

Limitations

Small sample size and study duration can affect the results of study. Comparison with inguinal exploration and large sample size is needed to prove superiority of laparoscopic exploration.

CONCLUSION

Laparoscopic exploration for IPT is a safe procedure of choice. Further randomized contro trail are

required to establish its superiority over inguinal exploration.

REFERENCES

1. Burjonrappa SC, Al Hazmi H, Barrieras D, Houle A-M, Franc-Guimond J. Laparoscopic orchidopexy: the easy way to go. *Journal of Pediatric Surgery*. 2009;44(11):2168-72.
2. Singh RR, Rajimwale A, Nour S. Laparoscopic management of impalpable testes: comparison of different techniques. *Pediatric Surgery International*. 2011;27(12):1327-30.
3. Shehata SM, Shehata SMK, A. Baky Fahmy M. The intra-abdominal testis: lessons from the past, and ideas for the future. *Pediatric Surgery International*. 2013;29(10):1039-45.
4. Arena S, Impellizzeri P, Perrone P, Scalfari G, Centorino A, Turiaco N, et al. Is inguinal orchidopexy still a current procedure in the treatment of intraabdominal testis in the era of laparoscopic surgery? *Journal of Pediatric Surgery*. 2017;52(4):650-2.
5. Shepard CL, Kraft KH. The Nonpalpable Testis: A Narrative Review. *The Journal of urology*. 2017;198(6):1410-7.
6. Thapa B, Pun M. Inguinal Exploration for the Management of Impalpable Undescended Testes 2017. 36 p.
7. Igarashi A, Kikuchi K, Ogushi K, Hasegawa M, Hatanaka M, Fujino J, et al. Surgical exploration for impalpable testis: Which should be first, inguinal exploration or laparoscopic abdominal exploration? *Journal of Pediatric Surgery*. 2017.
8. Abolyosr A. Laparoscopic versus open orchiopexy in the management of abdominal testis: a descriptive study. *International journal of urology : official journal of the Japanese Urological Association*. 2006;13(11):1421-4.
9. Elder JS. Surgical Management of the Undescended Testis: Recent Advances and Controversies. *European journal of pediatric surgery : official journal of Austrian Association of Pediatric Surgery [et al] = Zeitschrift fur Kinderchirurgie*. 2016;26(5):418-26.
10. Sharifiaghdas F, Beigi FM. Impalpable testis: laparoscopy or inguinal canal exploration? *Scandinavian journal of urology and nephrology*. 2008;42(2):154-7.
11. Hrivataakis G, Astfalk W, Schmidt A, Hartwig A, Kugler T, Heim T, et al. The timing of surgery for undescended testis: a retrospective multicenter analysis. *Deutsches Ärzteblatt International*. 2014;111(39):649.

12. Bruijnen CJ, Vogels HD, Beasley SW. Age at orchidopexy as an indicator of the quality of regional child health services. *Journal of paediatrics and child health*. 2012;48(7):556-9.
13. Moursy EE, Gamal W, Hussein MM. Laparoscopic orchidopexy for non-palpable testes: outcome of two techniques. *Journal of pediatric urology*. 2011;7(2):178-81.
14. Alam A, Delto JC, Blachman-Braun R, Wayne G, Mittal AG, Castellan M, et al. Staged Fowler-Stephens and Single-stage Laparoscopic Orchidopexy for Intra-abdominal Testes: Is There a Difference? A Single Institution Experience. *Urology*. 2017;101:104-10.
15. Elyas R, Guerra LA, Pike J, DeCarli C, Betolli M, Bass J, et al. Is Staging Beneficial for Fowler-Stephens Orchidopexy? A Systematic Review. *The Journal of Urology*. 2010;183(5):2012-9.
16. Wang C-Y, Wang Y, Chen X-H, Wei X-Y, Chen F, Zhong M. Efficacy of single-stage and two-stage Fowler-Stephens laparoscopic orchidopexy in the treatment of intraabdominal high testis. *Asian journal of surgery*. 2017;40(6):490-4.
17. Singh RR, Rajimwale A, Nour S. Laparoscopic management of impalpable testes: comparison of different techniques. *Pediatr Surg Int*. 2011;27(12):1327-30.
18. Budianto IR, Tan HL, Kinoshita Y, Tamba RP, Leiri S, Taguchi T. Role of laparoscopy and ultrasound in the management of "impalpable testis" in children. *Asian journal of surgery*. 2014;37(4):200-4.
19. Pirgon Ö, Dündar BN. Vanishing Testes: A Literature Review. *Journal of Clinical Research in Pediatric Endocrinology*. 2012;4(3):116-20.
20. Nataraja RM, Asher CM, Nash R, Murphy FL. Is routine excision of testicular remnants in testicular regression syndrome indicated?. *Journal of pediatric urology*. 2015 Jun 1;11(3):151-e-5.

CONFLICT OF INTEREST: Authors declare no conflict of interest

GRANT SUPPORT AND FINANCIAL DISCLOSURE NIL

AUTHOR'S CONTRIBUTION

Following authors have made substantial contributions to the manuscript as under:

- Rahman FU:** Data analysis and Drafting.
Rahman I: Conception of idea and critical review.
Imran M: Data interpretation & Final approval to be Published.
Akhtar W: Data collection & literature Review.

Authors agree to be accountable for all aspects of the work in ensuring that questions related to the accuracy or integrity of any part of the work are appropriately investigated and resolved.