

# MARTIUS LABIAL FAT PAD INTERPOSITION IN COMPLICATED VESICOVAGINAL FISTULA

Mazhar Khan<sup>1</sup>, Zahid Aman<sup>1</sup>, Sadia Nawaz<sup>2</sup>, Siddique Ahmad<sup>1</sup>, Mohammad Alam<sup>1</sup>

<sup>1</sup>Department of Surgery, Postgraduate Medical Institute, Hayatabad Medical Complex, Peshawar - Pakistan

<sup>2</sup>Department of Surgery, Khyber Teaching Hospital, Peshawar - Pakistan

## ABSTRACT

**Objective:** To assess the out come of Martius Labial fat pad interposition in the repair of complex low or medium vesicovaginal fistulas.

**Material and Methods:** A prospective study, carried out in surgical units of Khyber Teaching Hospital, Peshawar and Hayatabad Medical Complex, Peshawar. Patients with complex low or medium vesicovaginal fistula were included. Study period was from Jan 1997 to Dec 2006. Repair was done through the vaginal approach. Martius labial fat pad was taken from the left side in all patients. Patients were followed up for 6 months.

**Results:** Total of 32 patients were included in the study. Age range was from 15 years to 40 years, with mean age being 27 ( $\pm$  4 SD) years. Obstetric trauma accounted for 78.13% cases while 12.5 % cases were due to abdominal hysterectomy. Postoperative transient stress incontinence occurred in 12.5% patients, while recurrence of the vesicovaginal fistula was seen in 12.5 % patients.

**Conclusion:** Martius labial fat pad is a simple, safe and effective technique for the repair of complex vesicovaginal fistula.

**Key Words:** Vesicovaginal fistula, Complex fistula, Martius labial fat pad.

## INTRODUCTION

Urinary fistula to the vagina has been described as early as ancient times by Hippocrates and Rufus<sup>1</sup>. Before the nineteenth century, the urinary fistulae were generally considered to be irreparable but in the mid to late 1800s, James Marion Simms not only introduced the routine use of postoperative catheter drainage of the bladder but also described the surgical technique for fistula repair<sup>2</sup>. During the early 20<sup>th</sup> century, several additional techniques were used to improve the outcome for repair of vesicovaginal fistula. Many surgeons introduced flaps for interposition between bladder and vaginal walls to minimize the failure of vesicovaginal fistula repair.

The actual incidence of genitourinary fistula is not known. However, according to WHO estimates, over five million women develop genitourinary fistulae each year<sup>3</sup>. This is associated with significant decrease in quality of life for the unfortunate patient.

In industrialized nations, gynecologic surgery is the most common cause of vesicovaginal fistula. Abdominal or vaginal hysterectomy are associated with about 75% of genitourinary fistula<sup>1</sup>. Obstetric injury is

the major cause of urinary fistulae in underdeveloped nations due to limited medical resources<sup>1,3,4,5</sup>. Other causes of vesicovaginal fistula include urologic or gastrointestinal pelvic surgery, pelvic malignancy, pelvic radiation, and rarely infection including urinary tuberculosis<sup>1,6</sup>. Erosion by foreign bodies including pessaries has also resulted in vesicovaginal fistula formation<sup>1,7</sup>.

Management of vesicovaginal fistula is complicated by the presence of substantial tissue loss and the tendency of the repair to break down<sup>8</sup>. Numerous methods for repair of vesicovaginal fistula have been described. Abdominal, transvaginal or combined abdomino-vaginal approaches are used for the repair of the fistula<sup>1</sup>. Tissue interposition is indicated in the management of complicated vesicovaginal fistulae such as giant vesicovaginal fistula larger than 5 cm in diameter, multiple or recurrent vesicovaginal fistulae and those associated with radiation therapy. Tissue interposition is justified since there is often insufficient and poorly vascularized tissue for second layer of closure<sup>1,3</sup>. Martius labial fat pad is commonly used to reinforce the fistula repair<sup>3,8</sup>. It provides a well vascularised tissue and a surface for epithelialisation and prevents overlapping of vesical and vaginal suture lines<sup>1,3,8</sup>.

The purpose of our study was to assess the results of Martius labial fat pad in the repair of complicated vesicovaginal fistula.

---

### Address for Correspondence:

**Dr. Mazhar Khan**

Professor Surgical Unit,  
PGMI/HMC, Peshawar.  
Contact No. 091-9217140

## MATERIAL AND METHODS

A prospective study was conducted on patients with complicated vesicovaginal fistulae in the surgical units of Khyber Teaching Hospital Peshawar and Hayatabad Medical Complex, Peshawar. The study period was from January 1997 to December 2006.

All patients with recurrent or giant vesicovaginal fistulae i.e. more than 5cm in diameter were included in the study. Patients with uncomplicated fistula, high vesicovaginal fistula, ureterovaginal fistula and urethrovaginal fistula were excluded from the study. Informed consent was taken from all the patients. Mechanical bowel preparation was done and triple sulphamethoxazole vaginal cream pack was placed on the night before surgery. All patients had 1gm of Amikacin ½ hours before operation.

All the cases were operated upon by a single surgeon. Cystoscopy for identification of the fistula and bilateral ureteric catheterization with 6 Fr ureteric catheters was done in all the patients immediately before surgery.

Repair was done via vaginal route. Patients were put in lithotomy position. The fistula was dissected to separate bladder from vagina and the bladder was closed with 2/0 vicryl continuous sutures. Martius labial fat pad was raised via longitudinal incision on the left labia major in all patients. The vascular bundle at the anterior portion of the fat pad was divided while the branches of internal pudendal vessel at the posterior aspect were preserved for nourishing the flap. By blunt dissection, a tunnel was made through which the fat pad was pulled across into the fistula site. The pad was secured to the bladder, covering the fistula, with 2/0 vicryl. Vaginal flap was loosely closed over the fat pad with continuous 2/0 vicryl. A suction drain left into labia major via a separate stab incision. Labial skin was closed with subcuticular prolene suture. Bilateral ureteric catheters were removed after completion of the surgery. Two way silicon catheter 16 Fr was placed per urethra in all patients. Vaginal pack was placed at the end of the repair. Postoperatively, the patients were mobilized after 24 hours. Suction drain and vaginal pack were removed after 48 hours. Patients were discharged on the 5<sup>th</sup> or 6<sup>th</sup> postoperative day. Urethral catheter was removed after one month.

Patients were asked to come for follow up at one month, three months and six months after operation. Total duration of follow up was six months.

## RESULTS

A total of 32 patients were included in the study. Age ranged from 15-40 yrs, with a mean age of 27 yrs, as shown in Table 1. There were 22(68.75%) primipara and 10 (31.25%) multipara patients.

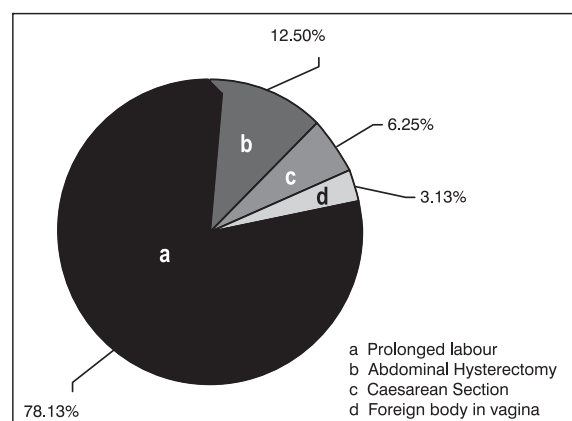
Regarding etiology of vesicovaginal fistulae, 25 (78.13%) patients had obstetrical history of prolonged labour and instrumental delivery. Abdominal hysterectomy accounted for 4 (12.5%) cases of vesicovaginal fistulae for benign uterine pathology as elective surgery. Caesarean section due to obstructed labour accounted for 2 (6.25%) cases of vesicovaginal fistulas. One patient had a large vaginal stone formed over a left over swab, that resulted in vesicovaginal fistula, as shown in figure 1.

**Table 1: Patient Age**

S. #	Age	No. of patients
1.	15-25 yrs	4 (12.5%)
2.	26-35 yrs	25 (78.13%)
3.	36-40 yrs	3 (9.4%)

**Table 2: Postoperative Complications**

S. #	Complications	No. of patients & %age
1.	Haematuria	5 (15.62%)
2.	Clot retention	1 (3.12%)
3.	Vaginal bleeding	2 (6.25%)
4.	Labial wound infection	2 (6.25%)
5.	Transient stress incontinence	4 (12.5%)
6.	Recurrence	4 (12.5%)
7.	Deep vein thrombosis	1 (3.12%)
8.	Constipation	1 (3.12%)



**Fig. 1: Etiology Of Vesicovaginal Fistula**

During the follow up, 12.5% patients had transient stress incontinence for three months. Recurrence of vesicovaginal fistula was seen in 4 (12.5%) cases, as shown in Table 2. Two (6.25%) patients had labial wound infection which didn't need any intervention. Haematuria occurred in 5 (15.62%)

patients and clot retention in only one case. Bleeding through the vagina after removal of the pack occurred in 2 (6.25%) patients. However it stopped spontaneously. Deep venous thrombosis and constipation occurred in 1 (3.12%) patient each. 28 (87.5%) cases operated were successful with no postoperative urinary leak.

## DISCUSSION

Vesicovaginal fistula is a dreadful condition. Apart from urinary incontinence, there is perineal skin excoriation, discomfort and odor which cause serious social problems. Most of the patients with genitourinary fistulas are young primipara<sup>9</sup>. In this study 22 (68.75%) patients were primipara and only 10 (31.25%) patients were multipara.

Most cases of vesicovaginal fistula in developing countries result from obstetrical trauma due to prolonged difficult labor<sup>4,5,9,10</sup>. High frequency of vesicovaginal fistula in Pakistan and other developing countries is because of poor medical care and low socioeconomic status<sup>9,10</sup>.

In our study, 78.13% of the vesicovaginal fistulae were due to obstetrical trauma and only 12.5% were due to abdominal hysterectomy. These figures are consistent with other local studies<sup>3,9</sup>. A recent Nigerian article reported that 96.5% vesicovaginal fistulae were due to obstetrical trauma. Most of their patients had developed fistulae as a primigravida during a prolonged labour<sup>11</sup>. Similarly an African study on 230 patients reported that the obstetrical trauma was the causative factor in 93% of fistulae and most of the patients were young primiparas<sup>12</sup>.

An uncommon cause of vesicovaginal fistula is the presence of foreign body in the vagina for prolonged duration<sup>7</sup>. We had only one such case. A young girl who had a history of road traffic accident in childhood, dressing pad was placed in the vagina at that time, which had later eroded into the bladder creating the fistula.

A high index of clinical suspicion, coupled with diagnostic tests and appropriate surgical intervention results in excellent outcome in most cases. While some small fistulae less than 3.5mm in diameter, may respond to conservative management with continuous urethral catheter drainage<sup>13</sup>, or fulguration of the fistulous tract<sup>14</sup>, the definite treatment of the fistula is surgical repair<sup>1</sup>. Although controversy exists in the timing of fistula repair i.e. early versus delayed repair, we prefer operation after three months of occurrence or of the previous repair. By then local inflammation and infection have resolved, the scar is matured and the amount of tissue loss is better defined.

Many studies have reported that the success rate of repair of complex vesicovaginal fistula is improved with tissue interposition<sup>3,15</sup>. Martius labial fat pad is

commonly used to reinforce the repair of complicated fistula. This interposition flap is composed of bulbocavernosus muscle and the overlying fibro adipose tissue from the labia major. It receives its blood supply from the internal pudendal artery<sup>1,16,17</sup>.

Alternative interposition flaps include peritoneum, omentum, gracilis myocutaneous or myofascial flap and gluteal skin rotational flaps. These alternative interposition flaps are used when the repair site is beyond the reach of Martius labial fat pad such as in proximal vesicovaginal fistulae<sup>1,3,8,19</sup>.

Many studies have reported good results with Martius flap with low postoperative morbidity<sup>3,8,16,17,20-25</sup>. The success rate of Martius flap varies from 87-100%<sup>3,8,16,17,20</sup>. In our study 4 (12.5%) patients had recurrence of vesicovaginal fistula. These patients underwent successful repair after 3 months using Martius flap from the opposite side. Transient stress incontinence was noted in 4 (12.5%) cases, which improved spontaneously in 3 months and did not need any additional treatment. These figures are consistent with that of other studies<sup>3,8,25</sup>.

## CONCLUSION

Martius labial fat pad is a simple, safe and effective technique in the repair of complex vesicovaginal fistulae.

## REFERENCES

1. Leach GE, Trockman BA. Surgery for vesicovaginal and urethrovaginal fistula and urethral diverticulum. In: Wash PC, Retik AB, Vaughan ED, Wein AJ, editors. Campbell's urology. 7<sup>th</sup> edition. Philadelphia: W.B. Saunders Company, 1998; 1135-51.
2. Sims JM. On the treatment of vesico-vaginal fistula 1852. *Int Urogynecol J Pelvic Floor Dysfunct* 1998; 9: 236-48.
3. Puneekar SV, Buch DN, Soni AB, Swami G, Rao SR, Martius labial fatpad interposition and its modification in complex lower urinary fistulae. *J Postgraduate Med* 1999; 45: 69-73.
4. Biswas A, Bal R, Alauddin M, Saha S, Kundu MK, et al. Genital fistula our experience. *J Indian Med Assoc* 2007; 105: 123-26.
5. Arrowsmith S, Hamlin EC, Wall LL. Obstructed labor injury complex: obstetric fistula formation and the multifaceted morbidity of maternal birth trauma in the developing world. *Obstet Gynecol Surv*. 1996; 51: 568-74.
6. Moore KN, Gold MA, Mc Meekin DS, Zorn KK. Vesicovaginal fistula formation in patients with stage IV a cervical carcinoma. *Gynecol Oncol* 2007; 106: 498-501.
7. Siddiqui NY, Paraiso MF. Vesicovaginal fistula due to an unreported foreign body in an adolescent. *J Pediatr Adolesc Gynecol* 2007; 20: 253-5.

8. Rangnekar NP, Imdad Ali N, Kaul SA, Pathak HR. Role of the martius procedure in the management of urinary-vaginal fistulas. *J Am Coll Surg.* 2000; 191: 259-63.
9. Holem A, Breen M, Mac Arthur C. Obstetric fistulae: a study of women managed at the Monze Mission Hospital, Zambia. *GJOG* 2007; 114: 1010-17.
10. Korell AN, Argenta PA, Strathy JH. Prolonged obstructed labor causing a severe obstetric fistula: a case report. *J Reprod Med* 2007; 52: 555-56.
11. Wall LL, Karshima JA, Kirschner C, Arrowsmith SD. The obstetric vesicovaginal fistula: characteristics of 899 patients from Jos, Nigeria. *Am J Obstet Gynecol* 2004; 190: 1011-19.
12. Falandry L. Vesicovaginal fistula in Africa. 230 cases *Press Med* 1992; 21: 241-45.
13. Davits RJAM, Miranda SI. Conservative treatment of vesicovaginal fistulas by bladder drainage alone. *Br J Urol* 1991; 68:155-56.
14. Stovsky MD, Ignatoff IM, Blum MD, Nanninga M, O'Connor VJ, Kursh ED. Use of electrocoagulation in the treatment of vesicovaginal fistulas. *J Urol* 1994; 152: 1443-44.
15. Cortesse A, Colau A. Vesicovaginal fistula. *Ann Urol* 2004; 38: 52-66.
16. Elkins TE, De Lancey JO, Mc Guire EJ. The use of modified martius graft as an adjunctive technique in vesicovaginal and rectovaginal fistula repair. *Obstet Gynecol* 1990; 75: 727-33.
17. Elkins TE: Fistula surgery: past, present and future directions. *Int Urogynecol J Pelvic Floor Dysfunct* 1997; 8: 30-35.
18. Raz S, Bregg KJ, Nitti VW, Snssman E. Transvaginal repair of vesicovaginal fistula using a peritoneal flap. *J Urol* 1993; 150: 56-59.
19. Menchaca A, Akhyat M, Gleicher N, Gottlieb L, Bernstein J. The rectus abdominis muscle flap in a combined abdominovaginal repair of difficult vesicovaginal fistulae. A report of three cases. *J Reprod Med* 1990; 35: 565-68.
20. Falandry L, Lahaye F, Marara C. A pedicled muscle fat flap of the major labia in the treatment of complex vesicovaginal fistula. *J Urol (Paris)*. 1990; 96: 97-102.
21. Chassagne S, Haab F, Zimmermann P. The Martius flap in vaginal surgery: technique and indications. *Prog Urol.* 1997; 7: 120-25.
22. Baskin D, Tatlidede S, Karsidag SH. Martius repair in urethrovaginal defects. *J Pediatr Surg* 2005; 40: 1489-91.
23. Margolis T, Elkins TE, Elkins TE, Seffah J, Oparo-Addo HS, Fort D. Full thickness Martius grafts to preserve vaginal depth as an adjunct in the repair of large obstetric fistulas. *Obstet Gynecol* 1994; 84: 148-52.
24. Tazi K, Moudouni SM, Rhorfi MA, Nouri M, Koutani A, fun Attya AA, et al. Martius technique in the treatment of complex Vesicovaginal fistula. *Ann Urol (Paris)*. 2001; 35: 344-48.
25. Djordjevic M, Stanojevic D, Perovic S. Our experience in the Martius method of closing the vesicovaginal fistula. *Acta Chir Iugos* 2004; 51: 101-13.

The Journal of Medical Sciences, Peshawar is indexed with WHO IMEMR (World Health Organisation Index Medicus for Eastern Mediterranean Region) and can be accessed at the following URL.

<http://www.who.int/EMRJorList/details.aspx?docn=4468>