

# SUCCESS RATE OF ULTRASOUND GUIDED HYDROSTATIC REDUCTION FOR CHILDHOOD INTUSSUSCEPTION

Muhammad Younas Khan<sup>1</sup>, Muhammad Uzair<sup>1</sup>, Muhammad Fayaz<sup>1</sup>, Kifayat Ullah<sup>1</sup>, Nadeem Ullah<sup>2</sup>

<sup>1</sup>Department of Paediatric Surgery, Lady Reading Hospital, Peshawar - Pakistan

<sup>2</sup>Department of Diagnostic Radiology, Lady Reading Hospital, Peshawar - Pakistan

## ABSTRACT

**Objective:** To study the success rate of ultrasound guided hydrostatic reduction for childhood intussusceptions.

**Material and Methods:** This study was conducted at the Paediatric Surgery and Radiology units of PGMI Lady Reading Hospital, Peshawar from November 2007 to November 2010. All patients with abdominal pain, per rectal bleeding, bilious vomiting and a palpable abdominal mass were subjected to an ultrasound scan. Those cases with ultrasound evidence of intussusception were included in the study. Data was analyzed by descriptive statistics.

**Results:** In three years there were eighty-five patients with ultrasound proven intussusception. Out of these, 50 patients were male, while 35 were female with a male to female ratio of 1.4:1. Apart from abdominal pain, 68(80%) patients presented with bleeding per rectum and 59 (69.41%) patients had a palpable mass. In 64(75.29%) patients successful reduction was accomplished. Hydrostatic reduction was impossible in 21 (24.1%) because of late presentation. One patient died because of septicemia. All the patients were followed for a period of 2-4 weeks.

**Conclusion:** Ultrasound-guided hydrostatic reduction is a feasible and effective method for the treatment of intussusception in children because of its radiation-sparing effect and high success rate.

**Key Words:** Intussusception, Hydrostatic reduction, abdominal mass, ultrasound.

## INTRODUCTION

Intussusception, which is defined as the telescoping or invagination of a proximal portion of intestine (intussusceptum) into a more distal portion (intussusciens), is one of the most common causes of bowel obstruction in infants and toddlers. In 1876, Hirschsprung first reported the technique of hydrostatic reduction<sup>1</sup> and after monitoring a series of 107 cases, reported a 35% mortality rate attributable to intussusception in 1905. The incidence of intussusception is 1.5-4 cases per 1000 live births, with a male-to-female ratio of 3:2<sup>2</sup>. The greatest incidence of idiopathic intussusception is in infants aged between 9 and 24 months<sup>3</sup>.

The clinical presentation is characterized by abdominal pain, per rectal bleeding, bilious vomiting and a palpable abdominal mass<sup>4</sup>. Depending on the affected bowel part, several types can be distinguished. Intussusception may be ileoileal, colocolic, ileoileocolic and ileocolic. Ileocolic is the most common type. Findings on plain radiographic examination of the abdomen include dilated loops of small bowel with or without air-fluid levels, an airless

or opacified right lower quadrant or both<sup>5,6</sup>. First reported as a useful diagnostic tool in intussusception by Burke in 1977, the utility of ultrasonography in the diagnosis of intussusception has been verified<sup>7-9</sup>.

The diagnostic enema is therapeutic in 80%-90% of patients. A successful therapeutic reduction must demonstrate free flow of contrast (air or barium) proximal to the ileocecal valve<sup>10-12</sup>. Previously unsuccessful attempts in enema reduction under fluoroscopic guidance was followed by surgery but now repeated attempts, taking in consideration the condition of the patient, is recommended<sup>13</sup>. Perforation is a risk with either barium or air but poses less of a problem with air, as the combination of barium and faeces may result in severe peritonitis with wide peritoneal soilage<sup>14,15</sup>. Pneumatic reduction with fluoroscopic guidance is claimed to be quick, safe, clean and it has been reported to have a high success rate. However, fluoroscopy also uses ionizing radiation, and it may not depict the lead point<sup>16</sup>.

Ultrasonography is advocated to aid in diagnosis and to assist with hydrostatic reduction of intussusception<sup>17</sup>. It is also a well-recognized alternative method for the reduction of childhood intussusception. The main advantage of hydrostatic reduction with ultrasound guidance is the avoidance of ionizing radiation, which is especially important in children<sup>18</sup>. As ultrasound is often the first-line imaging

### Address for Correspondence:

**Dr. Muhammad Younas Khan**

Assistant Professor

Paeds Surgery, Lady Reading Hospital, Peshawar - Pakistan

Cell: 0314-9040153

E-Mail: dryounas\_khan@yahoo.com

modality for the diagnosis of intussusception, the procedure can be performed successfully within the ultrasound room after the diagnosis is made. This is efficient and saves time, since the patient does not have to be taken to a different room for fluoroscopy. The purpose of this study was to evaluate the success rate of hydrostatic reduction of childhood intussusception by sonographic guidance. Safety was monitored by documenting frequency of complications and recurrence rate.

## MATERIAL AND METHODS

This study was conducted in the Department of Paediatric Surgery and Radiology Department, Lady Reading Hospital, Peshawar from November 2007 to November 2010. All 85 patients presenting in the outpatient or emergency departments with symptoms of abdominal pain, bilious vomiting and bleeding per rectum were subjected to an ultrasound scan irrespective of clinical findings of a palpable mass. Each patient was examined using ultrasound machine Toshiba Nemio 10 SSA-550A with 7.5 MHZ probe. Those patients aged more than 2 years, with signs of peritonitis, history of previous abdominal surgery and failed attempts before presenting were excluded from the study.

Permission from the "institutional Research and Ethics Board" of Lady Reading Hospital, Peshawar was obtained following explanation of current views on management of the condition. All eighty five patients with ultrasonological evidence of intussusception were admitted in the Paediatric Surgical Unit, Lady Reading Hospital, Peshawar. All these patients were put on intravenous fluids, antibiotics and had a nasogastric tube placed. Relevant investigations such as complete blood picture, blood grouping, serum electrolytes were also performed, so that in the case of failed attempt the patient should be immediately shifted to operation theatre. Informed consent was taken for open surgery. Hydrostatic reduction was performed in collaboration with the interventional radiologist.

After obtaining informed consent, patients were submitted to rectal catheterization using a size 22Fr Foley's catheter through which 0.9% normal saline, warmed to 37°C, was instilled without pressure, with the saline bag placed about 100 cm above the level of the patient. Progression of the saline solution to the point of intussusception was accomplished by ultrasound monitoring. Reduction was accelerated by compression and changing the patient to the lateral decubitus position. Reduction was considered successful when the intussusception disappeared, and when fluid and air bubbles were seen to pass from the caecum through the ileocaecal valve. Following failure of the first attempt, a second and third attempt was performed, each three minutes apart. Finally the

viability of the gut was confirmed by assessing the vascular flow to the involved segment with a color Doppler ultrasound. In cases where the hydrostatic reduction failed, open reduction was done. Oral intake was restricted post intervention till the presence of bowel sounds on auscultation and passage of stools. After successful hydrostatic reduction, repeat ultrasound scan was performed within the first 24 hours. The patients were reviewed after one week and one month in the outpatient department.

## RESULTS

In three years duration, eighty five patients presenting with abdominal pain and bilious vomiting to the department of Paediatric Surgery, Lady Reading Hospital, Peshawar had evidence of intussusception on ultrasound scans. Out of the total eighty five patients, 50 were male and 35 were female, with a male to female ratio of 1.4: 1. Age of the patients was between 4-24 months (Table 1). Most of the patients presented to us within 12-48 hours of start of symptoms (Figure 1). Vomiting, bleeding per rectum and abdomen pain were the most common presenting symptoms (Figure 2). Successful hydrostatic reduction was done in 64 patients while in 21 patients the hydrostatic reduction failed and surgery had to be performed.

**Table 1: Age distribution of patients (n=85)**

Age (months)	No. of patients & percentage
4-6	28 (32.94%)
7-12	41 (48.23%)
13-18	7 (8.23%)
19-24	9 (10.58%)

## DISCUSSION

Intussusception is a common cause of intestinal obstruction in infancy and early childhood. Non operative reduction of ileocolic intussusception in infants and children was initiated more than 80 years ago<sup>21</sup>. Kim and colleagues described hydrostatic reduction under ultrasound guidance in 1982. It is believed to be one of the most promising methods for non operative treatment of intussusception. The first large series of children treated with this method was reported in 1988<sup>20</sup>. The main advantage of hydrostatic reduction with ultrasound guidance is to avoid ionizing radiation. This is especially important in children. More over the patient can be directly observed and immediate diagnosis of intestinal perforation or other complications can be made. The current diagnosis and treatment of intussusception is highly time saving and has a valuable effect on patient prognosis<sup>22</sup>.

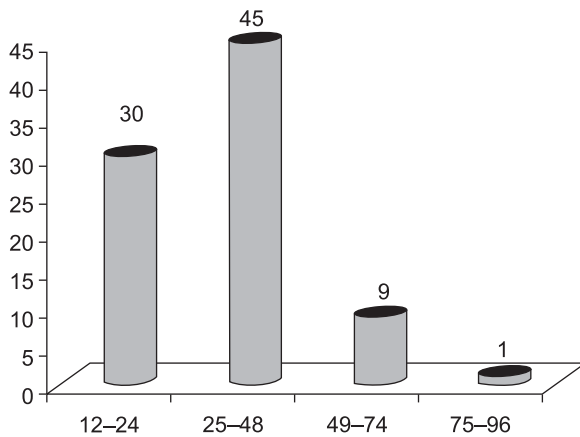


Fig. 1: Duration Of Illness

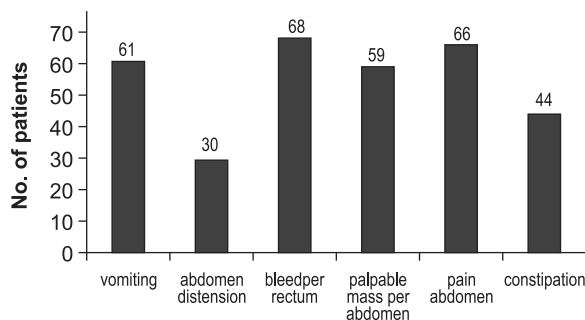


Fig 2: Symptoms

The age, sex, clinical findings and the rate of successful hydrostatic reduction in this study are comparable with other studies. Our results are also comparable with regional studies which show variable success rate i-e 60% reported by Sadeghipor S et al. and 94.5% reported by Sarin YK et al<sup>20,21</sup>. In our study the main presenting symptoms were abdominal pain in 66(77.65%) patients, bilious vomiting in 61(71.76%) patients, and bleeding per rectum in 68(80%) patients. In 1997, Peh W et al<sup>19</sup> compared the efficacy of ultrasonographically guided versus fluoroscopically guided hydrostatic reduction in 46 patients with intussusception. The ultrasound group had 3 recurrences (11.5%), 1 lead point (4.4%), and 19 successful reductions (73%); yet higher success rates have been documented in other Asian studies<sup>20</sup>.

Successful hydrostatic reduction was achieved in 64(75.29%) patients while in 21(24.71%) patients hydrostatic reduction failed because of late presentation. One patient died of septicemia. In our study, the rate of successful reduction was low in comparison to international western data<sup>22</sup>. This may be due to late presentation of the patients; however the results of our study are encouraging because it was an early experience with this procedure. During

ultrasound guided hydrostatic reduction no bowel perforation occurred in our study while some studies have reported colonic perforation in 0.17% patients<sup>23</sup>.

## CONCLUSION

Ultrasound-guided hydrostatic reduction of intussusception seems to be a feasible and effective method for the non operative treatment of intussusception in children because of its radiation-sparing effect, high success rate and cost effectiveness.

## REFERENCES

- Hirschsprung H. Et Tilfaelde af subakut tarmin-vagination. Hospitals-Tidende. 1876; 3: 312-27.
- Cosper GH, Hamann MS, Stiles A, Nakayama DK. Hospital characteristics affect outcomes for common pediatric surgical conditions. *Am Surg.* Aug 2006; 72(8): 739-45.
- Mahajan D, Nigam S, Kohli K. Abdominal tuberculosis presenting as ileocolic intussusception in an infant. *Pediatr Dev Pathol.* Nov Dec 2007; 10(6): 477-80.
- Sorantin E, Lindbichler F. Management of intussusception. *Eur Radiol.* 2004 Mar; 14 Suppl 4: 146-54.
- Roskind CG, Ruzal-Shapiro CB, Dowd EK, Dayan PS. Test characteristics of the 3-view abdominal radiograph series in the diagnosis of intussusception. *Pediatr Emerg Care.* Nov 2007; 23(11): 785-89.
- Park NH, Park SI, Park CS, Lee EJ, Kim MS, Ryu JA, et al. Ultrasonographic findings of small bowel intussusception, focusing on differentiation from ileocolic intussusception. *Br J Radiol.* Oct 2007; 80(958): 798-802.
- Oshio T, Ogata H, Takano S, Ishibashi H. Familial intussusception. *J Pediatr Surg.* Sep 2007; 42(9): 1509-14.
- Munden MM, Bruzzi JF, Coley BD, Munden RF. Sonography of pediatric small-bowel intussusception: differentiating surgical from nonsurgical cases. *AJR Am J Roentgenol.* Jan 2007; 188(1): 275-79.
- Eshel G, Barr J, Heiman E, et al. Incidence of recurrent intussusception following barium versus air enema. *Acta Paediatr.* May 1997; 86(5): 545-46.
- Hooker RL, Hernanz-Schulman M, Yu C, Kan JH. Radiographic evaluation of intussusception: utility of left-side-down decubitus view. *Radiology.* Sep 2008; 248(3): 987-94.
- Sargent MA, Wilson BP. Are hydrostatic and pneumatic methods of intussusception reduction comparable? *Pediatr Radiol.* 1991; 21(5): 346-49.
- Connolly B, Alton DJ, Ein SH, Daneman A. Partially reduced intussusception: when are repeated delayed

- reduction attempts appropriate? *Pediatr Radiol.* 1995; 25(2): 104-7.
14. Daneman A, Alton DJ, Ein S. Perforation during attempted intussusception reduction in children — a comparison of perforation with barium and air. *Pediatr Radiol.* 1995; 25(2): 81-88.
  15. Daneman A, Alton DJ. Intussusception. Issues and controversies related to diagnosis and reduction. *Radiol Clin North Am.* Jul 1996; 34(4): 743-56.
  16. Fragoso AC, Campos M, Tavares C, Costa-Pereira A, Estevão-Costa J. Pneumatic reduction of childhood intussusception. Is prediction of failure important? *J Pediatr Surg.* Sep 2007; 42(9): 1504-8.
  17. Bai YZ, Qu RB, Wang GD, Zhang KR, Li Y, Huang Y, et al. Ultrasound-guided hydrostatic reduction of intussusceptions by saline enema: a review of 5218 cases in 17 years. *Am J Surg.* Sep 2006; 192(3): 273-75.
  18. Wiersma F, Allema JH, Holscher HC. Ileoileal intussusception in children: ultrasonographic differentiation from ileocolic intussusception. *Pediatr Radiol.* Nov 2006; 36(11): 1177-81.
  19. Peh WC, Khong PL, Lam C, Chan KL, Saing H, Cheng W, Mya GH, Lam WW, Leong LL, Low LC. Ileoileocolic intussusception in children: diagnosis and significance. *Br J Radiol.* 2007; 70: 891-96.
  20. Sadeghipor S, Esfandiari H, Alamdaran A, Zandi B. Ultrasound-Guided Hydrostatic Reduction of Childhood Intussusceptions Using Water Enema. *Ir J Med Sci* 2008; 31 (4): 224-27.
  21. Sarin YK, Rao JS, Stephen E. Ultrasound guided water enema for hydrostatic reduction of childhood intussusceptions a preliminary experience *Indian J Radiol Imaging* 1999; 9: 59-63.
  22. Soun DS, Choy PC, Tok TS, Chiu CY. Reduction of intussusception by ultrasound guided saline enema. *Radiol Imaging* 1996; 37: 257-62.
  23. Bai YZ, Qu RB, Wang GD, Zhang KR, Li Y, Huang Y et al. Ultrasound-guided hydrostatic reduction of intussusceptions by saline enema: a review of 5218 cases in 17 years. *Am J Surg* 2006; 192: 273-75.

## ONLINE SUBMISSION OF MANUSCRIPT

It is mandatory to submit the manuscripts at the following website of JMS. It is quick, convenient, cheap, requirement of HEC and paperless.

Website: **[www.jmedsci.com](http://www.jmedsci.com)**

The intending writers are expected to first register themselves and then attach/submit the manuscript. If processing fee is not submitted before should be deposited with Managing Editor in cash or can submit in the form of bank draft in the name of editor JMS. Also follow the format and check list of the Journal. Author agreement can be easily downloaded from our website. A duly signed author agreement must accompany initial submission of the manuscript.