

DELAYED PRIMARY REPAIR OF FLEXOR TENDON INJURY IN DISTAL FOREARM

Gulzar Saeed Ahmed¹, Syed Muhammad Ali¹, Mohammad Arif², Muhammad Inam²

¹Department of Orthopedic Surgery, Liaquat University of Medical & Health Sciences, Jamshoro, Sindh - Pakistan

²Department of Orthopedic and Spine Surgery, Hayatabad Medical Complex, Peshawar - Pakistan

ABSTRACT

Objective: To analyze the results of delayed primary tendon repair using modified Kessler technique in patients with flexor tendon injury in distal forearm (hand zone V).

Material and Methods: The study was conducted at Liaquat University Hospital and a private practice setup at Jamshoro from January 2010 to December 2011. A total of 50 adult patients were included in the study. The inclusion criteria were adult patients having injury with sharp objects in zone five of hand, presenting between 24 hours to 10 ten days after injury. The exclusion criteria were associated vascular injury requiring repair, nerve injury, diabetes mellitus, infection, and segmental loss in tendons. The primary outcome measures were, painless movement of tendon, full range of movement of finger or wrist joint associated with the repaired tendon. Secondary outcome measures were infection, limitation or painful movement of tendons, adhesions, dehiscence of repair leading to tendon rupture at the repair site. Surgery was performed under general anesthesia and tourniquet. The tendons were repaired with 3/0 proline, using modified Kessler technique.

Results: Out of 50 patients, 38 (76%) were male and 12 (24%) were female. The age range was between 20 to 65 years. Mean age was 34.40 years \pm 12.49 SD. The injury was caused by knife in 18(36%), glass in 16(32%), hatchet in 13(26%) and machine in 3 (6%) patients. Total number of tendon repaired was 115. (2.3 per patient). Tendon repair was performed within 24 hours of admission in all patients. Modified Kessler technique was performed in all tendons repairs. Thirty eight out of 50(76%) patients recovered fully and regained full range of pain free movement at wrist and fingers in 8 to 12 weeks time. Mean time of recovery was 8.8 days \pm 1.319 SD. Six patients (12%) developed early post operative superficial infection. These patients responded well to treatment and recovered normally in 8 to 12 weeks time. Four (8%) patients develop adhesions resulting in limitation of movement at fingers, and two (4%) patients develop rupture of tendon at the suture site, requiring second surgery.

Conclusion: Modified Kesslers suture technique of tendon repair is effective for delayed primary repair of flexor tendon injury in distal forearm (zone V).

Key Words: Tendon, repair, Modified Kessler.

INTRODUCTION

Injuries to the flexor tendons are common. As the flexor tendon in hand and forearm lie close to the skin, the usual causes are, lacerations from sharp objects, crush injuries and sometime rupture from the site of insertion at bone during contact sports. These injuries could pose a challenge to orthopedic surgeon. The surgical intervention is always required to bring the ends together. The post operative management requires a careful planning as mobilization is essential to prevent adhesions and the risk of rupture is always there¹.

If the tendon is repaired within 12 hours of injury it is called primary tendon repair. In rare circumstances this time can be extended up to 24 hours. The delayed primary repair is the one which is performed within 24 hours to approximately 10 days after the injury. After 10 to 14 days the repair is called secondary repair, and after four weeks, it is called late secondary repair².

The flexor surface of hand is divided into five zones. Zone I extends from just distal to the insertion of the sublimis tendon to the site of insertion of the profundus tendon. Zone II is the area between the distal palmar crease and the insertion of sublimis tendon. Zone III is the area between distal margin of transverse carpal ligament and the beginning of the area of pulleys or first annulus. Zone IV is the area covered by the transverse carpal ligament. Zone V is the area proximal to the transverse carpal ligament and includes the forearm³.

Address for Correspondence:

Dr. Gulzar Saeed Ahmed

Associate Prof. Orthopedic Surgery
Liaquat University of Medical & Health Sciences
Jamshoro Sindh Pakistan
Cell: +92 333 2601173
E-mail: gulzarsaeed@yahoo.com

The repair of tendons can be delayed for various reasons, e.g. other injuries requiring immediate surgical intervention, severe wound contamination, crushing injuries, soft tissue loss and multiple fractures. Under these circumstances, the condition of patient does not allow the definitive treatment of the tendons, and it is advised that wound should be kept clean and dressed till it becomes possible to carry out definitive management of tendon injury. A delay of two to three days has very low risk of complications if the wound is kept clean².

For the management of tendon injury, many repair techniques have been reported. The basic aim is to prevent adhesions, gap formation and post operative rupture. Modified rehabilitation programs have been developed to improve the results of surgery⁴. There has been a lot of stress for strong suture techniques as early post operative movement protocols have shown good results. Many reports suggest that more suture strands passing through the repair field increase stretching strength⁵.

But this type of complex suture techniques are difficult to perform and excessive manipulation of the tissues is required⁶. Modified Kessler technique is relatively easy to perform. There are various complications of tendon surgery. The immediate complications could be infection, tendon rupture, poor tendon gliding, and later on adhesion formation⁷. In our setup many patients with tendon injury present late. The aim of this study was to analyze the results of delayed primary tendon repair using modified Kessler technique in patients with flexor tendon injury in distal forearm (hand zone V).

MATERIAL AND METHODS

The study was conducted at Liaquat University Hospital and a private practice setup at Jamshoro from January 2010 to December 2011. A total of 50 adult patients were included in the study. The inclusion criteria were adult patients having injury with sharp objects in zone five. The exclusion criteria was associated vascular injury requiring repair, nerve injury, diabetes mellitus, infection, segmental loss in tendons, tendon injury more than ten days old. The primary outcome measures were, painless movement of tendon, full range of movement of finger or wrist joint associated with the repaired tendon. Secondary outcome measures were infection, limitation or painful movement of tendons, adhesions, dehiscence of repair leading to tendon rupture at the repair site. Patients presenting between 24 hours to 10 ten days after injury were included in the study.

Surgery was performed under general anesthesia and tourniquet. Prophylactic antibiotics (first generation cephalosporins) were given at the induction of anesthesia. The wound debridement was done and wounds were extended to expose the

tendons ends. The tendons ends were carefully matched, with attention to their location and level of wound. The tendons were repaired with 3/0 proline, using modified Kessler technique (Figure 1). A suture was passed through the tip of the finger nail for controlled active motion programme as advised by Kleinert et al^{8,1}. The wound was closed with 3/0 proline. A dorsal splint was applied to hold the wrist in 30 degrees of flexion and metacarpophalangeal joint at 40 to 60 degrees of flexion. The interphalangeal joints were splinted in extension. The suture placed at the finger tip was attached to a rubber band and the other end of rubber band was attached to safety pin which in turn was attached to the bandage on distal forearm. This arrangement keep the finger in flexion of 40 to 60 degrees at the proximal interphalangeal joint with no tension on the rubber band, and allows active extension at proximal interphalangeal joint. Starting from the first day after surgery, active extension exercises within the limitation of splint were encouraged. After three weeks the dorsal splint was removed, and rubber band with connecting hook to the wrist band was kept on for additional 3 weeks. The patient was encouraged to actively extend the digit against the resistance of the rubber band. Passive extension and active flexion was not permitted. The rubber band and wrist band was removed at 6 to 8 weeks. Strengthening exercises were allowed at 8 to 10 weeks.

The skin stitches were removed after two weeks in all patients. In case infection was detected the skin stitches were removed earlier². The data was entered and analyzed in statistical program SPSS Version 16.0. Qualitative variable such as Gender, mechanism of injury, complication, tendon repair and outcome (Good & Poor) were presented as n (%). Numerical variable like age (in years), time of injury and recovery were presented as mean \pm SD. No statistical test was applied due to descriptive data.

RESULTS

A total of 50 patients were included in the study. Thirty eight (76%) were male and 12 (24%) were female. The age range was between 20 to 65 years. The injury was caused by knife in 18(36%), glass in 16(32%), hatchet in 13(26%) and machine in 3 (6%) patients. Most of the injuries were in the distal part of forearm proximal to transverse carpal ligament. Fifteen patients reported 2 days, 23 patients 4 days and 8 patients 5 days and 4 patients 7 days after injury.

Complications were detected in 12(24%) patients. Six patients (12%) developed early post operative infection, four (8%) patients develop adhesions resulting in limitation of movement at fingers, and two (4%) patients who remove the posterior splint 2 to 3 weeks after surgery develop rupture of tendon at the suture site.

Table 1: Frequency of Complications & outcome (n=50)

Complications	No. of patients & %age
Infections	6(12.0)
Adhesion	4(8.0)
Rupture	2(4.0)
Out comes	
Poor	6(12.0)
Good	44(88.0)

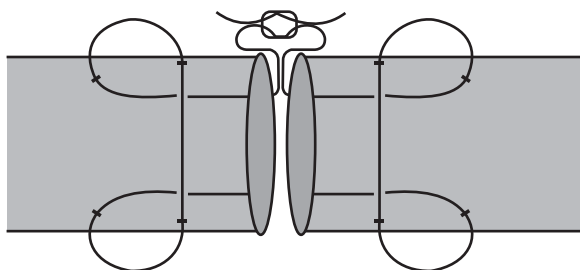


Fig. 1: Modified Kessler suture. Figure Error! Main Document Only.

Six patients with early post operative infection were treated with early removal of stitches, debridement and antibiotics according to culture and sensitivity. The infection was superficial and confined to skin. All the six patients responded very well and their later recovery was normal.

Four patients who develop adhesions, were non compliant to the early mobilization instructions. They did not regained full range of movements up to 12 weeks after repair. These four patients were operated for tenolysis 4 to 5 months after surgery and they recovered and regained full range of movement with 13 weeks of second surgery. Two patients develop rupture of tendon at the suture line within three weeks after surgery. They were operated again and the results were fair as the healed with some limitation of movement. The frequency of complications and outcome is shown in Table 1.

DISCUSSION

The Infection rate in our series was 12% which is very high by any standard. The infection was superficial and did not affect the final outcome in term of function. Reason for this high infection rate could be that all cases included in the study were presented late and delayed primary repair was done in all cases.

It has been shown in many studies that the strength of flexor tendon repair is directly proportional to the number of threads crossing the repair site⁹. Other studies have shown that this multi stands technique need lot of expertise and experience, because tendon handling is increased, as needle is passed many time

through cut ends. This may results into complications like uneven loading of tendons¹. A two strand tendon repair done with 4/0 suture has breaking strength of 20 to 30 N which is equal to approximately 2 to 3 kg of force^{10,11}. Thicker sutures and multiple strands can increase the strength of repair up to 70 N¹². It has also been said that increased breaking strength may not improve the quality of repair. As before breaking the repair starts to gap, gaping tendons increase friction^{13,14}.

Levent M. et al¹⁴ have shown that average tensile strength of 2 stand modified Kessler suture was 39.89±9.65 Newton (N), for 4 strand modified Kessler suture was 50.29 ± 11.24 N and for 4 strand Strickland technique the strength was 39.64 ± 9.14 N¹⁵. We found that the strength of modified Kessler suture was enough to sustain the postoperative stress at repair site as only two out of fifty patients (4%) develop rupture at repair site. The patients were non compliant to the rehabilitation program. There is huge evidence that careful rehabilitation program is mandatory to achieve favorable results. The early motion techniques have improved tendon healing with fewer complications and with better outcome¹⁶. We followed the controlled active motion program as advocated by Kleinert et al⁶. With this technique it is believed that repair site is not stretched and the movement promotes healing. It is observed that mobilized tendon heal quicker and develop greater strength and fewer adhesions as compared to immobilized tendons¹⁷.

Reoperation rate in our series was 12% while Dy CJ et al in their meta-analysis of 29 studies have reported 6%, 4% rupture and 4% adhesions¹⁸. Saini N et al has reported 3% tendon rupture, and 3% contracture¹⁹. Elliot D et al reported 3-9% rupture rate²⁰. Adhesion rate in our series was 8%. This is high as compared to the literature, and the reason is non compliance of patients to the early mobilization instructions. Manske PR was of the opinion that rupture can be due to the misuse of hand and up to 20% of patients will develop adhesions requiring tenolysis²¹.

CONCLUSION

Modified Kesslers suture technique of tendon repair is effective for delayed primary repair of flexor tendon injury in distal forearm (zone V).

REFERENCES

1. Griffin M, Hindocha S, Jordan D, Saleh M, Khan W. An Overview of The Management of Flexor Tendon Injuries. The Open Orthopedics journal, 2012, 6, (Suppl 1: M3) 28-35.
2. Phillip E. Wright II Flexor and Extensor Tendon Injuries, in Canale & Beaty: edits, Campbell's Operative Orthopedics, 11th ed. Chapter 63, Pg 3851-71 Copyright © 2007 Mosby.

3. Green DP, Pederson WC, Hotchkiss RN, Wolfe SW, Eds. *Greens Operative Hand Surgery*. 5th ed. Philadelphia, Pennsylvania: Elsevier Churchill 2005.
4. Lee H. Double loop locking suture: a technique of tendon repair for early Active mobilization. Part II: Clinical experience. *J Hand Surg [Am]* 1990; 15: 953-58.
5. Winters SC, Gelberman RH, Woo SL, Chan SS, Grewal R, Seiler JG 3rd. The effects of multiple-strand suture methods on the strength and excursion of repaired intrasynovial flexor tendons: a biomechanical study in dogs. *J Hand Surg [Am]* 1998; 23: 97-104.
6. Wagner WF Jr, Carroll C IV, Strickland JW, Heck DA, Toombs JP. A biomechanical comparison of techniques of flexor tendon repair. *J Hand Surg [Am]* 1994; 19: 979-83.
7. Ting J. Tendon injuries across the world. *Injury* 2006; 37: 1036-42.
8. Kleinert HE, Meares A: In quest of the solution to severed flexor tendons. *Clin Orthop Relat Res* 1974; 104: 23-30.
9. Savage R. In vitro studies of a new method of flexor tendon repair. *J Hand Surg* 1985; (10): 135-41.
10. Tanaka T, Amadio PC, Zhao C, et al. Gliding characteristics and gap formation for locking and grasping tendon repairs: A biomechanical study in a human cadaver model. *J Hand Surg [Am]* 2004; 29: 6-14.
11. Momose T, Amadio PC, Zhao C, et al. Suture techniques with high breaking strength and low gliding resistance: experiments in the dog flexor digitorum profundus tendon. *Acta Orthop Scand* 2001; 72: 635-41.
12. Erhard L, Zobitz ME, Zhao C, et al. Treatment of partial lacerations in flexor tendons by trimming: a biomechanical in vitro study. *J Bone Joint Surg [Am]* 2002; 84: 1006-12.
13. Coert JH, Uchiyama S, Amadio PC, et al. Flexor tendon-pulley interaction after tendon repair: a biomechanical study. *J Hand Surg [Br]* 1995; 20: 573-77.
14. Dinopoulos HT, Boyer MI, Burns ME. The resistance of a four- and eight-strand suture technique to gap formation during tensile testing: an experimental study of repaired canine flexor tendons after 10 days of in vivo healing. *J Hand Surg [Am]* 2000; 25: 489-98.
15. Yalçın L, Selman M, Dem RC, Mehmet ALP, Salih Murat Akkin, Burak Fiener, Jürgen Koebke. Biomechanical assessment of suture techniques used for tendon repair. *Acta Orthop Traumatol Turc* 2011; 45(6): 453-57.
16. Howell JW, Peck F. Rehabilitation of flexor and extensor tendon injuries in the hand: Current updates. *Injury*. 2013 Jan 21. pii: S0020-1383(13) 00035-1.
17. Tang JB. Indications, methods, postoperative motion and outcome evaluation of primary flexor tendon repairs in zone 2. *J Hand Surg Eur* 2007; 32: 118-29.
18. Dy CJ, Hernandez-Soria A, Ma Y, Roberts TR, Daluiski A. Complications after flexor tendon repair: a systematic review and meta-analysis *J Hand Surg Am*. 2012; 37(3): 543-51.
19. Saini N, Kundnani V, Patni P, Gupta S. Outcome of early active mobilization after flexor tendons repair in zones II-V in hand Indian *J Orthop*. 2010; 44(3): 314-21.
20. Elliot D, Moiemmen NS, Fleming AF, et al. The rupture rate of acute flexor tendon repairs mobilized by the controlled active motion regimen. *J Hand Surg Br* 1994; 19: 607-20.
21. Manske PR. Flexor tendon healing. *J Hand Surg Br* 1988; 13: 237-41.

The Journal of Medical Sciences, Peshawar is indexed with WHO IMEMR (World Health Organisation Index Medicus for Eastern Mediterranean Region) and can be accessed at the following URL.

<http://www.who.int/EMRJorList/details.aspx?docn=4468>