

CORROSIVE INDUCED GASTRIC OUTLET OBSTRUCTION AND ITS SURGICAL MANAGEMENT

Mohammad Imran¹, Waheed Akhtar¹, Muhammad Naeem², Ridhwan Wahab¹, Fayaz Ur Rehman¹, Inayat Ur Rehman¹

¹Department of Pediatric Surgery, Khyber Teaching Hospital, Peshawar - Pakistan

²Department of Surgery, Khyber Teaching Hospital, Peshawar - Pakistan

ABSTRACT

Objective: To assess the outcome of Bilroth 1 procedure for complete gastric outlet obstruction after corrosive ingestion in children.

Material and Method: This is a retrospective study of the outcome of Bilroth 1 procedure performed for corrosive injury of upper gastrointestinal tract due to acid ingestion who presented to Pediatric Surgery unit from April 2015 to April 2016. Case records of all the patients who had a complete gastric outlet obstruction were reviewed and those who had isolated gastric injury or stricture were made part of this study. All patients underwent Bilroth 1 as primary surgical modality and same team of surgeons performed these surgeries.

Results: This study includes 21 patients of which 14 (66.6%) were males and 7 (33.33%) were females. Mean age was from 3 years \pm 1 years. The time interval between ingestion of acid and arrival in Pediatric Surgical unit ranged from 30 to 45 days. The mean time between surgery and presentation was 55 \pm 7 days.

Conclusion: Gastric outlet obstruction due to acid ingestion should be managed surgically. Bilroth 1 should be the procedure of choice for complete pyloric obstruction and severely injured gastric mucosa.

Key Words: Gastric outlet obstruction, Corrosive ingestion. Bilroth 1 procedure.

This article may be cited as: Imran M, Akhtar W, Naeem M, Wahab R, Rehman Fu, Rehman Iu. Corrosive induced gastric outlet obstruction and its surgical management. *J Med Sci* 2017; 25: (3) 319-322.

INTRODUCTION

In developing countries like Pakistan, benign strictures of upper gastrointestinal tract are commonly caused by corrosive agents or acid ingestion. Hydrochloric acid is easily available in the market as sweeps and toilet cleaning agent and it is a common cause of gastric injury and results in antral strictures and gastric outlet obstruction.¹ Nowadays acid battery is a major source of these injuries because of severe load shedding in our country, as people use generators and UPS systems for which acid batteries are used. Most of our cases presented from hilly areas where there is more load shedding and children accidentally ingested battery acids.

Dr. Mohammad Imran (Corresponding Author)

Assistant Professor

Pediatric Surgery, Khyber Teaching Hospital,
Peshawar - Pakistan

Cell: +92-334-9080767

Email: drmi1971@gmail.com

Date Received: July 30, 2017

Date Revised: September 1, 2017

Date Accepted: October 20, 2017

Gastric outlet obstruction is an uncommon condition; however it is a well-known complication of acid ingestion. After ingestion, the acid tends to pool at gastric pylorus and results in reflex pyloric spasm therefore pylorus and antrum are the most commonly involved areas.²⁻⁵ Due to careless storage of these chemicals at homes and poor parental supervision, mostly children of younger age groups are susceptible and exposed to accidental acid ingestion.^{4,6} The upper GIT injury is caused by both alkali and acid when ingested.⁵ According to literature only 3.8% cases out of all the corrosive ingestion cases present with isolated pyloric stenosis, so it is a very rare entity.⁷ Our study is based on the management of these patients with acid ingestion as we received all the cases with history of acid ingestion and is focussed on early surgical management of the patients with complete gastric outlet obstruction. We selected Bilroth 1 as our surgical option for the treatment of these patients.

MATERIAL AND METHODS

This is a retrospective study of corrosive injury of upper GIT due to acid ingestion who presented to pediatric surgery unit from April 2015 to April 2016.

Corrosive induced gastric outlet obstruction and its surgical management

Case records of all the patients who had complete gastric outlet obstruction were reviewed and those who had isolated gastric injury or stricture were included in the study. Those who had esophageal involvement or partial gastric outlet obstruction (GOO) were excluded. Preoperative diagnosis and workup was done with early upper GI endoscopy and upper GI contrast studies. And the above criteria were followed. Routine base-line investigations were also done and all the patients were optimized before the surgery. All the patients underwent Bilroth 1 as primary surgical modality. These surgeries were carried by same team of surgeons.

RESULTS

This study includes 21 patients of which 14 (66.6%) were males and 7(33.3%) were females. Mean age was from 3 years \pm 1. The time interval between ingestion of acid and arrival in our unit ranged from 30 to 45 days. The mean time between surgery and presentation was 55 \pm 7 days. All the patients had a smooth post operative period except one who had anastomotic leak on day 5. The patient was re-operated and a gastro-jejunostomy was done but he died after developing sepsis. Rest of the patients was followed upto a period of 1 year and there were no signs and symptoms of obstruction such as vomiting, abdominal distention, constipation or intolerance to oral diet.

DISCUSSION

In developing countries like Pakistan, benign strictures of upper gastrointestinal tract are commonly caused by corrosive agents or acid ingestion. Acid mostly affects the antrum of stomach.¹ It is well known

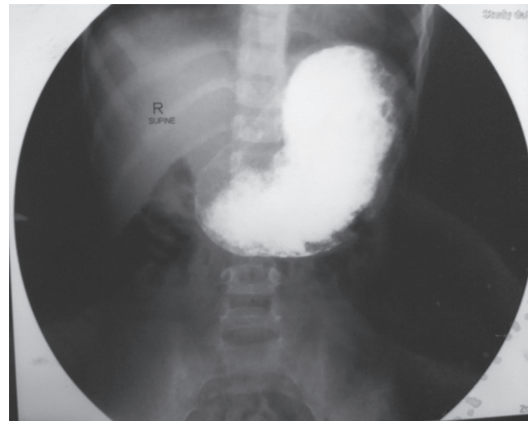


Figure 3: Barium Study

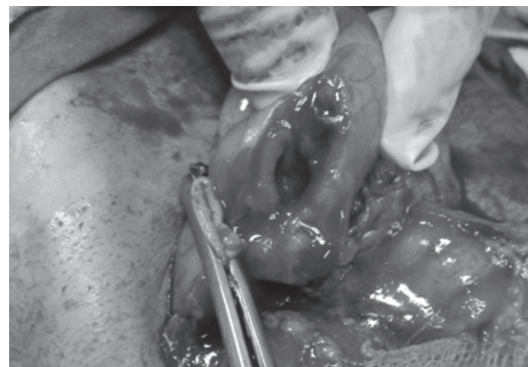

Figure 4: Per-operative picture

Table 1: Outcome of surgery

Primary Procedure	Follow up (months)	Outcome	Mortality
Bilroth 1	12 \pm 1	Satisfactory	1 (4.7%)

that “acids tend to lick the esophagus and bite the pyloric antrum”. Acids have low viscosity and low specific gravity as compared to liquid alkalis, hence acids pass quickly through the esophagus and mainly damage the antrum and pylorus of the stomach.⁸ This also results in antral spasm causing more damage to the antrum. The stomach is also more susceptible and vulnerable because it has columnar epithelium whereas esophagus has squamous epithelium which is more resilient.⁹ In another study it is stated that acid ingestion is responsible for 82.6% of chronic gastric injuries; the most of them had stenosis of pylorus.¹⁷

The extent of mucosal damage depends on the nature of the agent, the quantity and concentration of acid ingested, the mode of ingestion, the quantity of food already present in the stomach when acid is ingested. Most of the children present with vomiting, rapid weight loss and decreased oral intake.¹⁰ Early surgery is the treatment of choice and is recommended by most, though timing of surgery is still controversial.^{5,11}

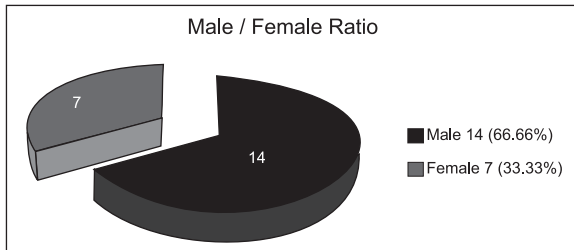


Figure 1: Male to female ratio

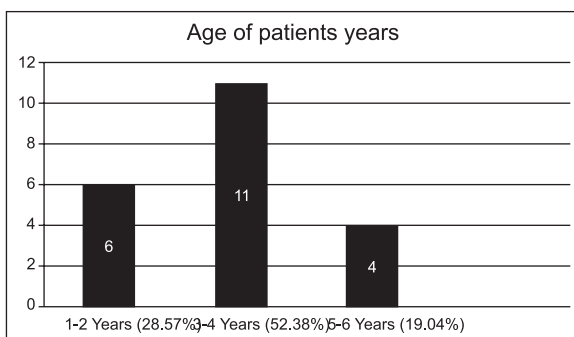


Figure 2: Age of patients

Like our study early surgical intervention is supported by literature. In one study, cases with complete gastric outlet obstruction were managed successfully by early surgical intervention.¹³ All our cases had no complaints of vomiting or postprandial fullness. All the patients were followed upto one year and did not reveal any morbidity.

The gastric outlet obstruction can develop as early as 7 days and as late as 6 years depending on the extent of gastric damage.¹² If there is no evidence of perforation in a patient, upper GI Endoscopy can be performed within 48 hours after the corrosive ingestion and has been recommended in most studies in patients without known perforation.^{2-5,8,12} A contrast study should be performed later in these patients to confirm the injury and look for any complications. The optimal surgical procedure is subject to degree of gastric outlet obstruction.

In our study all cases with complete gastric outlet obstruction were included. For patients with complete gastric outlet obstruction two procedures are performed, gastrojejunostomy; a simple bypass without any resection of the gut and the second one is gastric resection with restoration of gut continuity in form of gastroduodenal anastomosis. The dilemma is whether a simple bypass surgery like gastrojejunostomy would be acceptable or partial gastrectomy of the obstructed and gastroduodenal can be more appropriate. Özcan C performed gastrojejunostomy as procedure of 1st choice for all children who presented with gastric outlet obstruction due to acid ingestion. However Carcinoma, metaplasia and late marginal ulcers can develop in non-viable gastric tissues which remains there if resection is not done, as is the case in gastrojejunostomy.^{5,15,16} Hence early surgical correction is safer option and has reduced morbidity and mortality.⁵

Our choice of Bilroth 1 as surgical treatment of our cases is supported by literature. Billroth I in which we do antropylorectomy with gastroduodenostomy is a classic treatment for gastric outlet obstruction caused by acid ingestion. It is recommended in patients with complete gastric outlet obstruction which occurs when gastric mucosa is severely damaged. Antropylorectomy with gastroduodenostomy is a major surgery and there is doubt about the benefits and risks in children. In this procedure non-viable gastric tissue is also removed which can later on become malignant. So Bilroth 1 is 1st choice procedure in all age groups with gastric outlet obstruction due to acid ingestion. Kaushik R states that removal of non-viable gastric tissue is preferred and Bilroth I had good outcome.¹² Some studies recommend Bilroth I surgery in children with gastric outlet obstruction and reported uncomplicated outcomes.³⁻⁵

Gastric outlet obstruction can develop early or late but it's a complication of acid ingestion. 1,18 Some immediate complications of corrosive ingestion are upper respiratory tract injury (40% of cases) and significant dyspnea, stridor or edema of the larynx (5-15% of cases) requiring immediate intubation due to obvious airway compromise.^{2,19}

Many newer modalities of investigations have been studied. Lurie Y recently stated that CT scan has >90% specificity in predicting the need for operative intervention and eventual mortality, and the sensitivity was only > 30-40%. Based on these facts the authors concluded that CT scan cannot replace early endoscopy.²⁰

Endoscopic ultrasound has not shown any advantage in predicting immediate complications, time of surgery and later development of stricture.^{3,21} Endoscopic procedures have been attempted in treatment of gastric outlet obstruction but had limited success.^{22,23}

The main limitations of this study are that it is based on the patients who presented to Pediatric Surgical unit of KTH only from a limited number of patients belonging to KPK Province and moreover it is a retrospective study. However, the results are comparable to that documented in the literature. The limited number of cases are due to rarity of these kind of injuries.

CONCLUSION

Surgery is treatment of choice in patients with acid or corrosive ingestion who present with gastric outlet obstruction. Early endoscopy and per-operative findings are important in deciding about the type of procedure. In cases where there is complete gastric outlet obstruction and the gastric mucosa is severely damaged, Bilroth 1 is recommended. With a meticulous approach, Bilroth 1 surgery can give excellent outcome in patients with complete gastric outlet obstruction. All the patients should be under regular follow up for early detection of late complications and also to assure that gastrointestinal function is normal.

REFERENCES

1. Bilal M. Accidental Ingestion of Hydrochloric Acid causing acute gastric perforation in a child. *Journal of Surgery Pakistan* 2011;6: 45-6
2. Dogan Y, Erkan T, Çokugras FC, Kutlu T. Caustic gastroesophageal lesions in childhood: An analysis of 473 cases. *Clin Pediatr* 2006;45: 435-8.
3. Tekant G, Eroglu E, Erdogan E. Corrosive injury induced gastric outlet obstruction: A changing spectrum of agents and treatment. *J Pediatr Surg* 2001;36:1004-7.

Corrosive induced gastric outlet obstruction and its surgical management

4. Erdogan E, Eroglu E, Tekant G. Management of esophago-gastric corrosive injuries in children. *Eur J Pediatr Surg* 2003;13:289-93.
5. Ciftci AO, Senocak ME, Büyükpamukçu N, Hiçsönmez A. Gastric outlet obstruction due to corrosive ingestion: incidence and outcome. *Pediatr Surg Int* 1999;15:88-91.
6. Urganci N, Usta M, Kalyoncu D, Demirel E. Corrosive substance ingestion in children. *Indian J Pediatr* 2014;8: 675-9.
7. Lakshmi CP, Vijayhari R, Kate V, Ananthkrishnan N. A hospital-based epidemiological study of corrosive alimentary injuries with particular reference to the Indian experience. *Nat Med J India* 2013; 26: 31-6.
8. Gray HK, Holmes CL. Pyloric stenosis caused by corrosive substance: Report of a case. *Surg Clin North Am* 1948;28:1041-56.
9. Maggi AL, Meeroff M. Stenosis of the stomach caused by corrosive gastritis. *Gastroenterology* 1953; 24:573-8.
10. Sharma S, Debnath PR, Agrawal LD, Gupta V. Gastric outlet obstruction without oesophageal involvement: A late sequelae of acid ingestion in children. *J Indian Assoc Pediatr Surg* 2007;12:47-9.
11. Hwang TL, Chen MF. Surgical treatment of gastric outlet obstruction after corrosive injury - Can early definitive operation be used instead of staged operation? *Int Surg* 1996;81:119-21
12. Kaushik R, Singh R, Sharma R, Attri AK, Bawa AS. Corrosive induced gastric outlet obstruction. *Yonsei Med J* 2003;44: 991-4.
13. Shukla RM, Mukhopadhyay, MB, Tripathy KC, Mukhopadhyay B. Pyloric and antral strictures following corrosive acid ingestion: A report of four cases. *J Indian Assoc Pediatr Surg* 2010; 15(3):108-9. doi: 10.4103/0971-9261.71749
14. Özcan C, Ergün O, Sen T, Mutaf O. Gastric outlet obstruction secondary to acid ingestion in children. *J Pediatr Surg* 2004;39: 1651-3.
15. McAuley CE, Steed DL, Webster MW. Late sequelae of gastric acid injury. *Am J Surg* 1985;149: 412-5.
16. Kennedy SC, Bavaki AE. Corrosive damage to stomach stimulating carcinoma. *Br Med J* 1967;4:93-4.
17. Ananthkrishnan N, Parthasarathy G, Kate V. Chronic corrosive injuries of the stomach-a single unit experience of 109 patients over thirty years. *World J Surg* 2010; 34: 758-64.
18. Ozokutan BH, Ceylan H, Ertaşkin I, Yapici S. Pediatric gastric outlet obstruction following corrosive ingestion. *Pediatr Surg Int* 2010;26:615-8.
19. Adam O, Harvey JG, Holland AJA. Pediatric upper aero-digestive and respiratory tract burns. *Int J Burns Trauma* 2013;3: 209-13.
20. Lurie Y, Slotky M, Fischer D, Shreter R, Bentur Y. The role of chest and abdominal computed tomography in assessing the severity of acute corrosive ingestion. *ClinToxicol (Phila)* 2013;51:834-7.
21. Bonnici KS, Wood DM, Dargan PI. Should computerised tomography replace endoscopy in the evaluation of symptomatic ingestion of corrosive substances? *ClinToxicol (Phila)* 2014;16:1-15.
22. Hsun CC. Update on endoscopic management of gastric outlet obstruction in children. *World J Gastrointest Endosc* 2016; 8: 635-45.
23. Rafeey M, Ghोजazadeh M, Sheikhi S, Vahedi L. Caustic ingestion in children: a systematic review and meta-analysis. *J Caring Sci* 2016; 5: 251-65. doi: 10.15171/jcs.2016.027.

CONFLICT OF INTEREST: Authors declare no conflict of interest

GRANT SUPPORT AND FINANCIAL DISCLOSURE NIL

AUTHOR'S CONTRIBUTION

Following authors have made substantial contributions to the manuscript as under:

Imran M:	Drafting of manuscript
Akhtar W:	Idea and data collection
Naeem M:	Data collection
Wahab M:	Data collection
Rehman I:	Supervised the research
Rehman F:	Data collection

Authors agree to be accountable for all aspects of the work in ensuring that questions related to the accuracy or integrity of any part of the work are appropriately investigated and resolved.