

TRAUMATIC PERFORATION OF TYMPANIC MEMBRANE

Abdur Rehman¹, Ghareeb Nawaz², Arif Raza Khan³

¹Department of ENT, Gaju Khan Medical College and Bacha Khan Medical Complex, Swabi - Pakistan

²Department of ENT, Khyber Girls Medical College, Peshawar - Pakistan

³Department of ENT, Khyber Teaching Hospital, Peshawar - Pakistan

ABSTRACT

Objectives: To assess the causes, pattern and outcome of traumatic perforation of tympanic membrane and its impact on hearing impairment.

Material and Methods: A prospective study of tympanic membrane perforation by trauma was conducted in ENT Departments of District Headquarter Hospital, Swabi and Khyber Teaching Hospital, Peshawar from January 2010 to December 2011 in outpatient setting. A total of 91 cases were collected including 55 female and 36 male with age range from 2 years to 55 years.

Results: The major causes of traumatic perforation were open hand slap followed by penetrating injuries, road traffic accident, blast injury and baro trauma. The common site of perforation was posterior quadrant. 91% cases had a spontaneous healing during 3 month follow up.

Conclusion: The common cause of traumatic perforation of tympanic membrane in our setup is open hand slap. If not contaminated, spontaneous healing will occur within three months.

Key Words: Tympanic, membrane, trauma, perforation.

INTRODUCTION

Traumatic perforation of tympanic membrane is not an uncommon occurrence in ENT practice. Breaking the news of the perforation is usually worrying for the patient. Reassurance may be helpful in reducing the worry. Beside sharp injuries and other things causing direct damage to the drum in all other cases there is pressure changes around the tympanic membrane. Air compression alters air pressure on tympanic membrane from both the external auditory canal and middle ear.¹

It happens as a result of open hand slap, blasts, and scuba diving, sudden atmospheric pressure changes in aero plane during takeoff and landing and atmospheric pressure changes at high altitudes.² Some anesthetics and forceful blowing of nose also cause a sudden increase in middle ear pressure.³ Eustachian tube catheterization, politzerization, forceful suction in external auditory canal and pneumatic otoscopy can also cause damage to tympanic membrane. The causes which damage the drum directly are road traffic

accident, penetrating injuries, iatrogenic, manipulation of foreign body in the ear and ear syringing. Myringotomies may persist as perforation.⁴

The common symptoms are feeling of heaviness in the ear, hearing loss, tinnitus, bleeding from the ear, vertigo and a discharge when infected. Usually hearing loss is mild degree but moderate to severe when there is damage to ossicles or injury to oval or round window which gives a picture of mixed hearing loss. History of tinnitus and vertigo indicates inner ear damage. Healing of non infected uncomplicated traumatic perforation is usually satisfactory.⁵

MATERIAL & METHODS

The study was conducted in ENT OPD DHQ Hospital, Swabi. A total of 91 cases were included in the study, 55 female and 36 male with an age range from 2 years to 55 years. The study was completed in 2 years from January 2010 to December 2011. Only those cases were included in study who had a history of traumatic perforation. All cases were treated as outdoor patients and followed for a minimum of three month duration.

The diagnosis was made on otoscopic examination and hearing loss was assessed by tuning fork test and pure tone audiometry. The site of perforation was assessed on otoscopic examination. Patient

Address for Correspondence:

Dr. Abdur Rehman

Assistant Professor

ENT Department, Gaju Khan Medical College/Bacha Khan Medical Complex, Swabi - Pakistan

Cell: 0300-9084722

Email: drabdurrhmananwar@yahoo.com

were advised prophylactic antibiotics (amoxicycline or cephradine group) and analgesics, mefenamic acid or paracetamol orally and were advised to keep ear dry. Those already contaminated having signs of infections were advised antibiotic ear drops as well.

RESULTS

The major cause of traumatic perforation in the study was open hand slap (79%). Majority were females slapped by husband in domestic quarrels (40.6%), other were those slapped by school teachers (13.1%), policeman or security persons (9.8%) and 17.5% were result of interpersonal quarrels (street fights). Trauma by penetrating object was 2nd major group, most of them were children below 5 years of age who injured their tympanic membranes by introducing match stick, cotton bud or other solid and sharp object into the ear. Perforation caused as a result of blast injuries were 3.2%, those caused by scuba diving were 4.3% and barotraumas resulted in 2.1% cases of traumatic rupture of tympanic membrane while 8.7% were iatrogenic causes (Table 1 and Figure 1).

Table 1: Age wise distribution of cases

S. No.	Age in years	No. of cases and percentage
1.	01 to 10	15(16.4%)
2.	11 to 20	11(12.08%)
3.	21 to 30	20(21.9%)
4.	31 to 40	23(25.2%)
5.	41 to 50	13(14.2%)
6.	51 to 60	05(5.4%)
7.	61 to 70	04(4.3%)

Table 2: site of perforations

S. No.	Site	No. of cases and percentage
1.	Posterior half	65(71.00%)
2.	Anterior half	04(04.30%)
3.	Central part	18(19.70%)
4.	Attic	02(02.10%)
5.	Multiple sites	02(02.10%)

Table 3: Ear affected

S. No.	Ear	No. of cases and percentage
1.	Left Ear	63(69.20%)
2.	Right Ear	23(25.20%)
3.	Bilateral	5(05.40%)

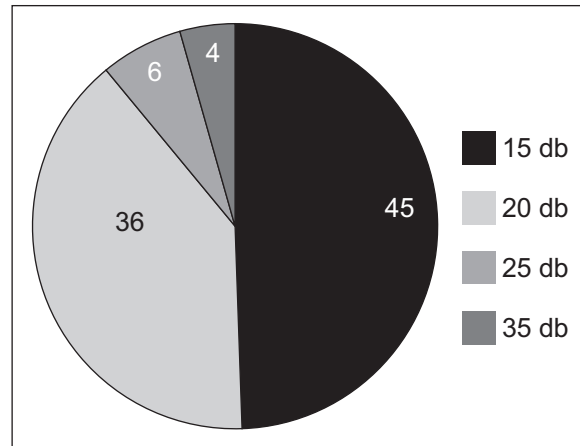


Figure 1: Hearing loss in dB

Age wise distribution of the patients is shown in Table 2. Majority of these patients reported to outdoor within 24 hours (90%) however some cases reported late either because they did not feel it serious or consulted initially a quack most of whom were mishandled. The most common site was in posterior half. 71% perforations occurred in post half, 19.7% in central part while 4.3% were situated in anterior half of tympanic membrane, 2.1% occurred in attic region while multiple perforations occurred in 2.1%. (Table 3)

Out of 91 total cases (94%) 86 patients had single ear affected while in 5 cases (5.4%) it was bilateral perforations. Most common ear affected was left (69.2%), Table 4. The degree of hearing loss after tympanometry is shown in Figure 1 and represented in Decibels (dB).

DISCUSSION

Perforated ear drum is a common entity encountered in ENT practice. The perforation caused by trauma is not an uncommon occurrence. Traumatic drum perforation is a worrying condition for the patient and also carries a significant medicolegal importance when caused by an assault, healing is almost sure when uncomplicated and remains none infected.⁶ In a study conducted by Orji FT, the incidence of infection in traumatic perforation was 20%, where as in our study it was 50%, difference is due to late presentation of patients to ENT departments and wrongly used aural drops, which are contra indicated in traumatic ear drum perforations.⁷

Infection is usually caused by ignorance, contamination by water especially by swimming in rivers and streams, unjustified syringing by so-called practitioners (Quacks) to relieve blocked feeling in the ears, and unjustified instillation of ear drops.

The common causes of traumatic perforation given in literature are road traffic accidents, assault, insertion of objects (bobby pins etc) into the ears, scuba diving, barotraumas at high altitudes and during air travel, and blasts.^{8,9,10} The common causes amongst

assault are open hand slap by security personale.¹¹ In our study the commonest cause of perforation was slap by husband in domestic quarrel. Second commonest cause was slap by school teacher. This is because of the social setup where there no risk of accountability or medicolegal consequences for husband and teacher. The trend and custom of beating women by husband is in vogue and beating children in schools by teachers still occur and using hand in the beating is a common trend. In difference studies conducted during the last 10 years, the incidence of slap trauma to school children was 0% in the West.^{12,13,14} Where as it was about 50 to 60% in the India¹⁵. The incidence of salp trauma in schools of Southern Africa was about 40%.¹⁶ Left ear was commonly involved in the perforation as the accused gave slap with right hand over left ear of the subject when face to face. The incidence of right or left ear traumatic perforation was about 70% in left ear and 30% in right ear in different studies.^{17,18,19} The blast and road traffic accidents cases are usually associated with other injuries as well and most of the time perforation is accompanied with damage to the middle ear and inner ear or both. This needs further evaluation by pure tone audiometry, CT scan or MRI once the patient is stable.⁸ A close watch for CSF otorrhoea is necessary.

CONCLUSION

It is important to avoid traumatic perforation in the ear, otherwise it may lead to severe deafness.

REFERENCES

1. Afolabi OA, Aremu SK, Alabi BS, Segun Busari S. Traumatic tympanic membrane perforation; an aetiological profile BMC Res notes, 2009; 2; 232.
2. Tang YM, Yang J. A prospective study evaluating spontaneous healing, aetiology, size and type – different groups of traumatic membrane perforation. Clinotolaryngol, 2011; 36(5); 450-60.
3. Fernand Luiz Westpha, Renato Telles, Luiz Callus Malia Dos. Tympanic membrane perforation caused by traumatic asphyxia J,Otorhinolaryngol. 2013; 79(1); 1221.
4. Kritensen S, Juvels, Gammelqaard N, Rasmussen OR. Traumatic perforation, complications and management. Ear Nose Throat J 1989 July 68(7); 503-16.
5. Griffen WL JA Retrospective study of traumatic perforation, A clinical practice. Laryngoscope 1979 Feb; 89; 261-82.
6. Orji FT, Aqucc. Determinants of spontaneous healing in traumatic perforation of tympanic membrane. Clinotolaryngol 2008 Oct 33 (5) 420-26.
7. Orji FT. Non explosive blast injury of tympanic membrane" prospective study" Niqer J Med 2009 Oct-Dec 18(4); 365-69.
8. De Palma R. Blast injuries, New England Journal of Medicine (2005) 352; 1335-41.
9. Beiter JT. Otopathology of Egyptian Mummy Part II J Laryngol Otol 1998. 10(2): 185-90.
10. Carr SD, Storechan DR, Raine CH. Factors affecting Myringoplasty success. J Laryngol Otol 2015. 129(1): 23-26.
11. Golz A, Netzer A, Jan Chim HZ. Ventilation tubes persisting tympanic membrane perforations. Otolaryngol Head Neck Surg 1999. 120(4): 524-27.
12. Orji FT, Agn CC. Determinants of spontaneous healing in traumatic perforation of the tympanic membrane. Clin Otorlaryngol 2008. 35(5): 420-26.
13. Park H, Hong SN, Kim HS. Determinants of conductive hearing loss in tympanic membrane perforation. Clin Exp Otorhinolaryngol. 2015. 8(2): 92-96.
14. Dursun E, Dogu S, Gungor A. Comparison of paper patch fat and perichondrium Myringoplasty in repair of small tympanic membrane perforations. Otolaryngol Head Neck Surg 2008. 138(3): 353-56.
15. Niklasson A, Tan K. The gelfoam plug an alternative treatment for small ear drum perforations. Laryngoscope 2011. 121(4): 782-84.
16. Pareth A, Mantle B, Banks J, Swart JD, Badylak SF. Repair of tympanic membrane with urinary bladder matrix. Laryngoscope 2009. 119(6): 2106-13.
17. Hekseven N, Akduman D, Solmaz Z. Inlay butterfly cartilage tympanoplasty in treatment of dry central perforation. Eur Arch Otorhinolaryngol. 2014. 73(7): 941-43.
18. Konaki E, Koyumen M, Ural R. Repair of subtotal tympanic membrane with sepra film. Laryngol Otol 2004. 118(11): 862-65.
19. Sakagamin M, Mishiro YT, Suzuki K. Bilateral same day surgery for bilateral perforated chronic otitis media. Aunis Nasus Larynx 2000. 27(1): 35-38.

AUTHOR'S CONTRIBUTION

Following authors have made substantial contributions to the manuscript as under:

Rehman A: Idea and data collection.

Nawaz G: Statistics and references.

Khan AR: Final corrections.

Authors agree to be accountable for all aspects of the work in ensuring that questions related to the accuracy or integrity of any part of the work are appropriately investigated and resolved.

CONFLICT OF INTEREST: Authors declare no conflict of interest

GRANT SUPPORT AND FINANCIAL DISCLOSURE NIL