

# THE SUCCESS AND COMPLICATIONS OF ENDOSCOPIC ENDONASAL MULTI-LAYER TECHNIQUE FOR THE MANAGEMENT OF SPONTANEOUS CEREBROSPINAL FLUID (CSF) RHINORRHEA

Imran Khan<sup>1</sup>, Muhammad Osama<sup>2</sup>, Israr Ud din<sup>1</sup>, Shakir Ullah<sup>1</sup>, Nazneen Liaqat<sup>1</sup>, Khalil Ahmad Orakzai<sup>3</sup>, Mashal Khan<sup>4</sup>

<sup>1</sup>Department of ENT, Khyber Teaching Hospital, Peshawar - Pakistan

<sup>2</sup>Department of Medicine, Hayatabad Medical Complex, Peshawar - Pakistan

<sup>3</sup>Department of ENT, Lady Reading Hospital, Peshawar - Pakistan

<sup>4</sup>Department of ENT, Hayatabad Medical Complex, Peshawar - Pakistan

## ABSTRACT

**Objective:** To determine the success and complications of endoscopic endonasal multi-layer technique for the management of spontaneous cerebrospinal fluid (CSF) rhinorrhea

**Materials and Methods:** This descriptive chart review was conducted at Khyber Teaching Hospital and involved thirty-four patients with spontaneous CSF rhinorrhea confirmed by MRI. Exclusions included trauma, previous surgery, and tumors. The primary outcome was the success rate of the endoscopic endonasal approach and associated complications. Patients underwent endoscopic repair under general anesthesia. Postoperative care included strict bed rest, prophylactic antibiotics, and regular follow-up evaluations.

**Results:** The participants had a mean age of  $37 \pm 14.3$  years, with a female predominance (67.65%). The mean BMI was  $28 \pm 3.6$ , with 74% of patients having a BMI over 25. Preoperative imaging identified the cribriform plate as the most frequent leak site (64.71%). The most common complication was meningocele (5.8%). One patient had idiopathic intracranial hypertension (2.9%). All patients underwent successful endoscopic endonasal multi-layer repair, achieving a 97.06% success rate. Postoperative complications included nasal crusting (14.71%), sinusitis (11.76%), and a brief postoperative CSF leak (2.94%), which resolved spontaneously. One patient required a secondary repair. Follow-ups at one and three months confirmed the durability of the repairs, with no recurrence of CSF leaks.

**Conclusion:** The endoscopic technique is effective for managing spontaneous CSF rhinorrhea, demonstrating a high success rate with minimal complications. These findings support minimally invasive approaches in CSF leak management, emphasizing the importance of patient demographics and comorbidities in treatment planning.

**Keywords:** CSF Rhinorrhea, Endoscopic repair, Endoscopic endonasal multi-layer technique

---

**This article may be cited as:** Khan I, Osama M, Din IU, Ullah S, Liaqat N, Orakzai KA, et al. The Success And Complications Of Endoscopic Endonasal Multi-Layer Technique For The Management Of Spontaneous Cerebrospinal Fluid (CSF) Rhinorrhea. *J Med Sci* 2025 January - March;33(1):37-42

---

## INTRODUCTION

Spontaneous cerebrospinal fluid (CSF) rhinorrhea is a rare condition of CSF leakage into the nasal sinuses and passages from a tear in the meninges due to a non-traumatic cause. Most CSF rhinorrhea cases are secondary to head injuries (80% to 90%) while a few are spontaneous. <sup>1</sup> Skull base bony defects and tumors are often seen in non-traumatic cases. <sup>2,3</sup> These leaks are common-

ly present as a breach between the skull base and dura of meninges through defects in the cribriform plate anteriorly and temporal bone laterally, often accompanied by brain hernia, a condition known as encephalocele. <sup>4</sup> The cribriform plate is the most frequent location due to its fragility and the proximity of the arachnoid layer with olfactory nerve passage through it. <sup>5</sup>

Middle-aged women with obesity are frequently identified as high-risk populations for spontaneous CSF leaks. <sup>6,7</sup> The predominant manifestations encompass orthostatic headache, nausea, and neck pain in order of frequency. Moreover, tinnitus, anosmia, and dysgeusia might also manifest as plausible clinical evidence. <sup>8</sup> They are often accompanied by complications including meningitis and tension pneumocephalus. <sup>9</sup>

Schlosser et al. have postulated the etiology of

### Correspondence

**Dr. Muhammad Osama**

Postgraduate Trainee

Department of Medicine, Hayatabad Medical Complex, Peshawar - Pakistan

**Cell:** +92-335-9191754

**Email:** mdosamaa1999@gamil.com

**Date Received:** 28-07-2024

**Date Revised:** 30/12/2024

**Date Accepted:** 13/01/2025

spontaneous CSF leaks as a variant of benign intracranial hypertension (BIH).<sup>10</sup> Radiological findings often point to BIH, with observations such as an empty sella, enlarged periodic CSF spaces, tortuosity of the optic nerve, and bilateral transverse sinus stenosis in the absence of thrombosis.<sup>11, 12</sup>

Endoscopic repair has emerged as a minimally invasive and increasingly preferred approach for the repair of CSF leaks of diverse origins at the anterior skull base.<sup>13</sup> It is embraced as an efficacious modality compared to conventional open surgeries, with higher success rates and reduced morbidity.<sup>14</sup>

This study aims to evaluate the management of spontaneous CSF rhinorrhea using the endoscopic endonasal multi-layer technique and its success rate by presenting a comprehensive analysis of thirty-four patients. Thus, this research endeavors to elucidate the potential role of endoscopic techniques in the broader landscape of CSF leak management.

## MATERIALS AND METHODS

It was a descriptive chart review of 34 patients (incident cases in the last year from Jan 2023 to Jan 2024), retrospective in nature, conducted at the otolaryngology department of Khyber Teaching Hospital Peshawar. The study protocol was approved by the Institutional Research and Ethical Review Board (IREB) of Khyber Medical College Peshawar under reference number (64/DME/KMC dated 27/11/2023). Informed consent from patients was waived because of the retrospective nature of the study. Every aspect of this study was according to the Declaration of Helsinki 1964 and the amendments that followed.

Patients' data were extracted from the hospital's electronic health record system database/paper-based health records from the hospital. The collected data included demographic variables like age, gender, and Body Mass Index (BMI), presenting complaints, diagnostic investigations carried out and documented medical and surgical history as written by the attending doctor. Comprehensive details regarding the surgical procedure done including the type of procedure and post-operative care and follow-up were also retrieved. Patients who presented with spontaneous CSF leak, as confirmed by magnetic resonance imaging (MRI) were only included. Those with a history of trauma, previous surgery, and brain or skull base tumors were excluded for accurate analysis of results.

As documented in the health records of the patients, a comprehensive radiological assessment was conducted preoperatively in all instances to precisely determine the location and dimensions of the defect, as well as to identify any associated complication, such as meningoencephalocele or meningocele. Radiological indicators of heightened intracranial pressure (ICP) were also carefully

scrutinized. It involved a contrast Computed Tomography (CT) scan and T2-weighted Magnetic Resonance Imaging (MRI) with contrast in the prone position, and a late venogram. Furthermore, consistent monitoring of serum electrolytes was implemented. As a prophylactic measure, patients were kept on oral third-generation cephalosporin (cefepodoxime) 200 mg every 12 hours, in combination with oral acetazolamide 250 mg every 6 hours, and syrup potassium chloride 5-10 mL every 24 hours (to prevent hypokalemia) until the definitive surgical intervention. Faculty from neurosurgery and radiology disciplines were also consulted regarding the management plan.

All participants underwent an endoscopic endonasal multi-layer restoration of the imperfection under general anesthesia. The location of the CSF leakage was verified intraoperatively by executing a Valsalva maneuver, involving the elevation of intraabdominal pressure by an anesthesiologist. The surgical field was exposed with dissection of adjacent turbinate and sinuses endoscopically. If present, meningoceles and meningoencephaloceles were reduced in standard fashion. The imperfection was then repaired, employing either adipose tissue or fascia lata graft (if measured <1 cm or had a low-flow leakage) or a vascularized nasoseptal flap (if measured >1 cm or had a high-flow leakage). A two-component fibrin sealant (Tisseel; Baxter Healthcare, Deerfield, IL) known as tissue glue, was administered for mending purposes in every instance. During the procedure, a CSF diversion technique was implemented, where lumbar drain (LD) insertion was performed on individuals with high-flow leaks. LDs were subsequently removed if there was no evidence of CSF leak.

Postoperatively, absolute bed rest for five days with the head positioned at a 30-degree angle was recommended for all cases. Each patient was administered prophylactic ceftriaxone injections of 2 grams every 12 hours for 5 days, followed by oral cefepodoxime 200 mg every 12 hours for 10 days. The regimen also included oral acetazolamide 250 mg every 6 hours, in conjunction with syrup potassium chloride at a dosage of 5 to 10 mL every 24 hours, aimed at preventing hypokalemia. Upon discharge, patients were instructed to gradually reduce the dosages over six to eighteen weeks. Patients were followed up on two visits, one month and three months period post-operatively. They were subjected to nasal endoscopy and MRI with contrast to look for primary outcomes. A surgical success was assigned if the defect was closed with no recurrence of CSF leak.

Data was analyzed using SPSS software version 24.0 ((IBM Corp, Armonk, NY, USA). All the quantitative variables are presented in the form of mean and standard deviation. While qualitative variables are presented as frequency and percentages.

**RESULTS**

The mean age of the 34 patients in the cohort was  $39 \pm 14.3$  years. The majority (23, 67.65%) were females. The mean BMI stood at  $28 \pm 3.6$ , with data indicating that 26 patients (76%) had a BMI exceeding 25. Among the comorbidities observed, hypertension was the most prevalent (4, 11.76%), as shown in Table 1. Symptoms upon presentation mainly featured thin watery nasal discharge, especially on exertion and when bending over.

Preoperative imaging successfully identified CSF leak sites in all patients, with the cribriform plate being the most frequent site (Figure 1; 22 patients, 64.71%). The most common complication was meningocele (Supplementary Figure 1, 4; 2 patients, 5.8%). Idiopathic intracranial hypertension (BIH), as indicated by an empty sella (Figure 2), was found in only one patient (2.9%), as shown in Table 2. The most common defect size was 7-10 mm in 12 patients (35.2%) followed by 3-6 mm in 11 patients (32.3%). Table 02. Intraoperative CSF leak was experienced by 23 patients (68%). Utilizing endoscopic endonasal sinus surgery (Figure 03), the middle turbinate flap emerged as the most commonly employed technique (18, 52.94%) Supplementary Table 01.

Postoperative hospitalization lasted an average of 2 days for all participants. As outlined in Supplementary Table 02, during the follow-up period, nasal crusting was observed in five patients (14.71%) while sinusitis developed in four patients (11.76%) and was appropriately managed. Two patients (5.8%) experienced a postoperative CSF leak; one at the one-month follow-up, which spontaneously resolved, and another patient on the 14th

**Table No 1: Characteristics of patients**

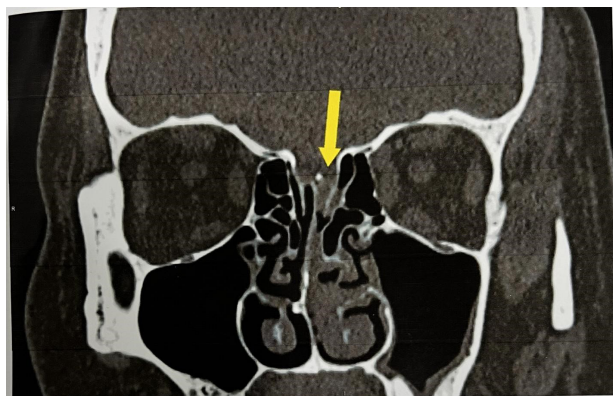
Demographics			
Age (mean $\pm$ SD), years	39 $\pm$ 14.3		
BMI (mean $\pm$ SD), kg/m2	28 $\pm$ 3.6		
Female Patients	23 (68%)		
Co-morbidities	Number	Percentage	
Hypertension	4	11.74	
Morbid Obesity*	2	5.88	
CRSWNP	1	2.94	
BMI-wise patient distribution	Male	Female	
< 18.5	1		2.9
18.5-24.99	5	2	20.5
25-29.99	4	15	56
30 and above	1	6	20.5

\*BMI > 40, CRSWNP = Chronic rhinosinusitis with nasal polyp.

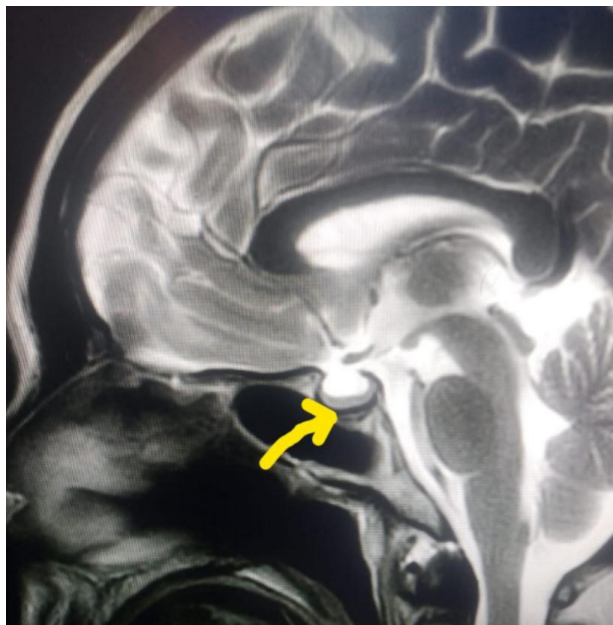
**Table No 2: CSF leak associated data**

Anatomical location of CSF leak			
	Cribriform plate, n (%)	Ethmoid roof, n (%)	Sphenoid sinus, n (%)
	22 (64.71)	9 (26.47)	3 (8.82)
Associated complication			
Meningocele	2 (5.88)	0 (0.00)	0 (0.00)
Meningoencephalocele	1 (2.94)	0 (0.00)	0 (0.00)
BIH	1 (2.94) (fig 2)	0 (0.00)	0 (0.00)
Meningitis	1 (2.94)	0 (0.00)	0 (0.00)
Defect size-wise distribution of patients			
Defect size	Number (n)	Percentage (%)	
<3mm	7	20.5	
3-6mm	11	32.3	
7-10mm	12	35.2	
1-2cm	3	8.8	
>2cm	1	2.9	

BIH = Benign intracranial hypertension



**Figure 1: Coronal CT scan of the paranasal sinuses showing an anterior CSF leak through a defect in the cribriform plate of the ethmoid bone (indicated by yellow arrow)**



**Figure 2: Axial T2-weighted MRI showing an empty sella (indicated by yellow arrow).**

postoperative day, was repaired again. The primary endoscopic repair procedure demonstrated an overall success rate of 97.06% (33/34 patients) in our investigation.

## DISCUSSION

Spontaneous CSF rhinorrhea is a rare condition that presents diagnostic and therapeutic challenges. In this retrospective study, we explored the management of 34 patients who underwent successful surgical management using the endoscopic endo-nasal multi-layer technique with an overall 97% success rate.

In our study, most of the presenting patients were middle-aged and females, with a 2.09:1 female-to-male ratio. Twenty-five patients had a BMI exceeding 25. These demographics align with previous studies indicating that spontaneous CSF rhinorrhea is more common in obese females.<sup>15, 16</sup> Although only one patient had BIH in our study, a strong association has been demonstrated between BIH and spontaneous CSF rhinorrhea previously.<sup>17</sup> Furthermore, some patients had underlying medical conditions such as hypertension, highlighting the potential relevance of comorbidities in CSF rhinorrhea management.

Thin watery discharge was the commonest presenting symptom which occurred most commonly during exertion and bending over, other studies do favor the findings.<sup>18</sup> Based on research findings, it is advisable to consider the possibility of spontaneous CSF rhinorrhea in individuals exhibiting elevated Sino-Nasal Outcome Test-22 (SNOT-22) scores for rhinorrhea, particularly when they identify this manifestation as their primary concern, but have lower scores related to the other cardinal symptoms of CRS.<sup>19</sup> In our study, we utilized various radiological modalities for preoperative assessment. These included contrast CT and T2-weighted MRI with contrast in the prone position, along with a late venogram to aid in localization and diagnosis, this aligns with other studies.<sup>20, 21</sup> Currently, Beta 2 transferrin is the gold standard for diagnosing CSF rhinorrhea, still, it cannot be used for localizing the site of leakage, imaging techniques such as volumetric extended echo train T2-weighted MRI and intrathecal gadolinium-enhanced spine MR imaging have shown promise in differentiating low- and high-flow CSF leaks, correlating with postoperative complications and recurrence rates.<sup>22</sup>

In our result the most common site of CSF leak is the cribriform plate (18/34 patients), the finding is consistent with literature<sup>23</sup>. Intraoperative encounters with CSF leaks were consistent across all cases. These findings align with the challenging nature of CSF rhinorrhea management, where the primary objective is to locate and repair the site of the leak effectively. Surgical techniques, including the use of flaps like the naso-septal flap and middle turbinate flap, were employed successfully in achieving durable repairs. These techniques have been recognized as valuable tools in the armamentarium for en-

doscopy CSF leak repair.<sup>24, 25</sup>

Surgical outcomes were favorable, with all patients achieving success, findings are similar to other studies.<sup>26</sup> Some patients experienced transient sinusitis postoperatively, which is not unexpected in endoscopic sinus surgery.<sup>27</sup> However, these cases were effectively managed, highlighting the importance of postoperative care. One patient presented with numbness in V2 distribution which was resolved after 2 weeks, this is consistent with the literature.<sup>28, 29</sup>

Follow-up data at the 1st and 3rd months post-surgery revealed sustained success and the absence of adverse radiological findings. This long-term follow-up is essential in assessing the durability of the surgical repair and the prevention of CSF leak recurrence. Our findings align with previous research stating that among the various approaches, defects repaired endo nasally had the lowest recurrence rate.<sup>30, 31</sup>

There are a few limitations in our study. It is a single-institution study with a small sample size. Some missing data could not be remedied due to the retrospective nature of the study. The relatively shorter follow-up period of 3 months limits the ability to assess long-term outcomes and the durability of the surgical repairs. The study does not compare the endoscopic endo-nasal multilayer technique to other surgical approaches, making it difficult to determine its relative effectiveness. Due to these factors, the findings may not be generalizable to other settings or populations with different demographics or clinical practices.

The study demonstrated a high success rate of 97.06% through comprehensive data collection and analysis, employing a minimally invasive surgical technique with detailed postoperative care and follow-up. However, its retrospective design, single-center nature, small sample size of 34 patients, and lack of a control group limit the generalizability and introduce inherent biases.

## CONCLUSION

Our study highlights the effectiveness and success rate of the endoscopic endo-nasal multi-layer technique for the surgical management of spontaneous CSF rhinorrhea. All patients achieved successful outcomes, with few minor side effects. Extended follow-up further supports the durability of the surgical repairs. These findings contribute to the evidence of a minimally invasive approach and underscore the importance of considering patient demographics, comorbidities, and financial factors in CSF rhinorrhea management.

## REFERENCES:

1. Oh JW, Kim SH, Whang K. Traumatic cerebrospinal fluid leak: Diagnosis and management. *Korean J Neurotrauma*. 2017 Oct;13(2):63. DOI: <https://doi.org/10.13004/>

- kjnt.2017.13.2.63
2. Filip P, Patel EA, Khalife S, Baird AM, Dominy C, Joshi K et al. Multiple skull base defects in the setting of spontaneous cerebrospinal fluid rhinorrhea; A dual institution view. *Am J Otolaryngol.* 2024 Jan-Feb;45(1):104048. DOI: <https://doi.org/10.1016/j.amjoto.2023.104048>
  3. Zhang F, Zeng T, Gao L, Cui DM, Wang K, Xu ZJ, Cao XY. Treatment of traumatic cerebrospinal fluid rhinorrhea via extended extradural anterior skull base approach. *Chin J Traumatol.* 2021 Sep 1;24(05):280-285. DOI: <https://doi.org/10.1016/J.CJTEE.2021.06.002>
  4. Lobo BC, Baumanis MM, Nelson RF. Surgical repair of spontaneous cerebrospinal fluid (CSF) leaks: A systematic review. *Laryngoscope Investig Otolaryngol.* 2017 Oct;2(5):215-224. DOI: <https://doi.org/10.1002/lio2.75>
  5. Ahilasamy N, Narendrakumar V, Rajendran DK, Sivaprakasam R. Cribriform CSF Leak: Endoscopic surgical repair using free septal mucosal graft without post-operative nasal packs. *Indian J Otolaryngol Head Neck Surg.* 2021 Sep;73:290-5. DOI: <https://doi.org/10.1007/s12070-020-02107-1>
  6. Durrant FG, Warner BK, Nguyen SA, Sturm JJ, Meyer TA. Elevated Body Mass Index associated with cerebrospinal fluid leak after lateral skull base surgery: A systematic review and meta-analysis. *Otol Neurotol.* 2023 Aug 1;44(7):636-42. DOI: <https://doi.org/10.1097/MAO.0000000000003914>
  7. Hentati F, Kocharyan A, Ruthberg J, Trudeau S, Jella T, Patil N, Cabrera CI, Mowry SE. Anterior and Lateral Skull Base Spontaneous CSF Leaks: Evaluation of Comorbidities and Treatment Outcomes. *Ann Otol Rhinol Laryngol.* 2023 Sep;132(9):1102-1109. DOI: [10.1177/00034894221134368](https://doi.org/10.1177/00034894221134368)
  8. Severson M, Schaurich CG, Strecker-McGraw MK. Cerebrospinal fluid leak. In: *StatPearls [Internet]* 2023 Mar 6. StatPearls Publishing. Available from: <https://www.ncbi.nlm.nih.gov/books/NBK538157/>
  9. Dong, Hyun, Seo., Kyung-Rae, Cho., Hyun, Seok, Lee., Kwan, Park. The diagnosis of cerebrospinal fluid leakage after microvascular decompression surgery and management via lumbar drain. *Daehan jeong'wi gi'neung sin'gyeong oe'gwa haghoeji,* (2022). DOI: <https://doi.org/10.52662/jksfn.2022.00248>
  10. Schlosser RJ, Woodworth BA, Wilensky EM, Grady MS, Bolger WE. Spontaneous cerebrospinal fluid leaks: a variant of benign intracranial hypertension. *Ann Otol Rhinol Laryngol.* 2006 Jul;115(7):495-500. DOI: <https://doi.org/10.1177/000348940611500703>
  11. Sivasankar R, Pant R, Indrajit IK, Negi RS, Sahu S, Hashim PI, D'Souza J. Imaging and interventions in idiopathic intracranial hypertension: a pictorial essay. *Indian Journal of Radiology and Imaging.* 2015 Oct;25(04):439-44. DOI: <https://doi.org/10.4103/0971-3026.169464>
  12. Degnan AJ, Levy LM. Pseudotumor cerebri: brief review of clinical syndrome and imaging findings. *American journal of neuroradiology.* 2011 Dec 1;32(11):1986-93. DOI: <https://doi.org/10.3174/ajnr.A2404>
  13. Mishra SK, Mathew GA, Paul RR, Asif SK, John M, Varghese AM, Kurien M. Endoscopic repair of CSF rhinorrhea: An institutional experience. *Iranian Journal of Otorhinolaryngology.* 2016 Jan;28(84):39. Available from: <https://www.ncbi.nlm.nih.gov/pmc/articles/PMC4735615/>
  14. Christoforidou A, Tsitsopoulos PP, Selviaridis P, Vital V, Constantinidis J. Endonasal endoscopic repair of cerebrospinal fluid leaks versus craniotomy: comparison of the outcomes. *Hippokratia.* 2016 Oct;20(4):299. Available from: <https://www.ncbi.nlm.nih.gov/pmc/articles/PMC5788229/>
  15. Quatre R, Attye A, Righini CA, Reyt E, Giai J, Scherber S, Karkas A. Spontaneous cerebrospinal fluid rhinorrhea: association with body weight and imaging data. *Journal of Neurological Surgery Part B: Skull Base.* 2017 Oct;78(05):419-24. DOI: <https://doi.org/10.1055/s-0037-1603731>
  16. Son HJ, Karkas A, Buchanan P, Giurintano JP, Theodosopoulos P, Pensak ML, Samy RN. Spontaneous cerebrospinal fluid effusion of the temporal bone: repair, audiological outcomes, and obesity. *The Laryngoscope.* 2014 May;124(5):1204-8. DOI: <https://doi.org/10.1002/lary.24484>
  17. de Macedo Filho L, Machado CCP, Mendes GBB, Santana LMF, Ruella ME, Grewal S, et al. Spontaneous rhinorrhea and idiopathic intracranial hypertension: a complex and challenging association. *Neurol Neurochir Pol.* 2024;58(1):31-37. DOI: <https://doi.org/10.5603/pjnns.98054>
  18. Hong CS, Kundishora AJ, Elsamadicy AA, Vining EM, Manes RP, Omay SB. A unique subset: idiopathic intracranial hypertension presenting as spontaneous CSF leak of the anterior skull base. *Journal of Neurological Surgery Part B: Skull Base.* 2022 Apr;83(02):105-15. DOI: <https://doi.org/10.1055/S-0040-1716898>
  19. Liu MY, Gardner JR, Woodworth BA, Jang DW, Kanaan A, Radabaugh JP et al. Individual SNOT-22 Items Aid in Differentiating Between Spontaneous Cerebrospinal Fluid Rhinorrhea and Chronic Rhinosinusitis Without Nasal Polyps. *Ann Otol Rhinol Laryngol.* 2023 Jun;132(6):698-704. DOI: <https://doi.org/10.1177/00034894221111256>
  20. He WJ, Zhang XJ, Xu QZ, Bai RT, Chen JK, Zhou X, Xia J. Are preoperative phase-contrast CSF flow parameters ideal for predicting the outcome of shunt surgery in patients with idiopathic normal pressure hydrocephalus?. *Frontiers in Neurology.* 2022 Sep 27;13:959450. DOI: <https://doi.org/10.3389/fneur.2022.959450>
  21. Rutland JW, Govindaraj S, Gill CM, Shohet M, Iloreta AM, Bederson JB, Shrivastava RK, Delman BN. Correlation of spontaneous and traumatic anterior skull base CSF leak flow rates with fluid pattern on early, delayed, and subtraction volumetric extended echo train T2-weighted MRI. *Journal of Neurosurgery.* 2019 Dec 27;134(1):286-94. DOI: <https://doi.org/10.3171/2019.10.JNS192500>
  22. Dobrocky T, Winklehner A, Breiding PS, Grunder L, Peschi G, Häni L, Mosimann PJ, Branca M, Kaesmacher J, Mordasini P, Raabe A. Spine MRI in spontaneous intracranial hypotension for CSF leak detection: nonsuperiority of intrathecal gadolinium to heavily T2-weighted fat-saturated sequences. *American Journal of Neuroradiology.* 2020 Jul 1;41(7):1309-15. DOI: <https://doi.org/10.3174/AJNR.A6592>

23. Martin TJ, Loehrl TA. Endoscopic CSF leak repair. Current opinion in otolaryngology & head and neck surgery. 2007 Feb 1;15(1):35-9. DOI: <https://doi.org/10.1097/MOO.0b013e3280123fce>
24. Manimaran V, Lakshmanan S, Prateep A, Baburajan R. Outcomes of Middle Turbinate Flap in the Reconstruction of Non-tumorous Ventral Skull Base Defects Institutional Review. Turkish archives of otorhinolaryngology. 2020 Dec;58(4):214. DOI: <https://doi.org/10.5152/tao.2020.5743>
25. Carnevale C, Til-Pérez G, Tomás-Barberán M, Ibañez-Domínguez J, Arancibia-Tagle D, Sarría-Echeagaray P. Middle turbinate mucosal flap: Low-morbidity option in the management of skull base defects. Head & Neck. 2021 May;43(5):1415-20. DOI: <https://doi.org/10.1002/hed.26613>
26. Deenadayal DS, Vidyasagar D, Naveen Kumar M, Sudhakshin P, Sharath Chandra SV, Hameed S. Spontaneous CSF rhinorrhea our experience. Indian Journal of Otolaryngology and Head & Neck Surgery. 2013 Aug; 65:271-5. DOI: <https://doi.org/10.1007/s12070-011-0431-3>
27. Tan BK, Chandra RK. Postoperative prevention and treatment of complications after sinus surgery. Otolaryngologic Clinics of North America. 2010 Aug 1;43(4):769-79. DOI: <https://doi.org/10.1016/j.otc.2010.04.004>
28. Robinson SR, Baird R, Le T, Wormald PJ. The incidence of complications after canine fossa puncture performed during endoscopic sinus surgery. American journal of rhinology. 2005 Mar;19(2):203-6. DOI: <https://doi.org/10.1177/194589240501900215>
29. Lee JJ, Kim D, Ryu G, Kim HY, Dhong HJ, Chung SK, Hong SD. Comparison between endoscopic prelacrimal medial maxillectomy and Caldwell-Luc approach for benign maxillary sinus tumors. Clinical and Experimental Otorhinolaryngology. 2019 Aug 1;12(3):287-93. DOI: <https://doi.org/10.21053/ceo.2018.01165>
30. Gassner HG, Ponikau JU, Sherris DA, Kern EB. CSF rhinorrhea: 95 consecutive surgical cases with long-term follow-up at the Mayo Clinic. American Journal of Rhinology. 1999 Nov;13(6):439-48. DOI: <https://doi.org/10.2500/105065899781329610>
31. Kirtane MV, Gautham K, Upadhyaya SR. Endoscopic CSF rhinorrhea closure: our experience in 267 cases. Otolaryngology—Head and Neck Surgery. 2005 Feb;132(2):208-12. DOI: <https://doi.org/10.1016/j.otohns.2004.09.004>

**CONFLICT OF INTEREST:** Authors declare no conflict of interest

**GRANT SUPPORT AND FINANCIAL DISCLOSURE:** NIL

**Authors Contribution:**

Following authors have made substantial contributions to the manuscript as under

Authors	Conceived & designed the analysis	Collected the data	Contributed data or analysis tools	Performed the analysis	Wrote the paper	Other contribution
Khan I	✓	✗	✓	✗	✓	✗
Osama M	✓	✓	✗	✓	✓	✗
Din IU	✗	✓	✗	✗	✓	✗
Ullah S	✓	✓	✓	✗	✓	✓
Liaqat N	✓	✓	✗	✓	✓	✗
Orakzai KA	✓	✓	✗	✓	✓	✗
Khan M	✗	✓	✗	✗	✓	✗

Authors agree to be accountable for all aspects of the work in ensuring that questions related to the accuracy or integrity of any part of the work are appropriately investigated and resolved.

**Ethical Approval:**

**This Manuscript was approved by the Ethical Review Board of (IREB) of Khyber Medical College/Khyber Teaching Hospital Peshawar. Vide No. 614/DME/KMC. Dated: 27 11 2023**



This work is Licensed under a Creative Commons Attribution-(CC BY 4.0)