

# CLINICAL CASE REPORT: TUBEROUS SCLEROSIS COMPLEX

Mahnoor Raza, Saleem Iqbal

Department of Medicine, Khyber Teaching Hospital, Peshawar - Pakistan

## ABSTRACT

Tuberous sclerosis complex is an autosomal dominant genetic disorder that affects multiple systems, resulting in the formation of hamartomas in different organs such as the skin, central nervous system, kidneys, and lungs. This leads to a variety of symptoms, ranging from seizures to skin manifestations. Here, we report a case of a 14-year-old male child who presented with myoclonic fits and fever. He was eventually diagnosed to be suffering from tuberous sclerosis, based on his clinical signs and investigations.

**KEYWORDS:** Fever, Seizures, Hamartomas, Tuberous Sclerosis

**This article may be cited as:** Raza M, Iqbal S. Clinical Case Report: Tuberous Sclerosis Complex. J Med Sci 2025 January - March;33(1):48-51

## INTRODUCTION

Tuberous sclerosis/Bourneville disease is a genetic disorder that affects cellular differentiation, proliferation, and migration in early embryonic development, which subsequently leads to the formation of hamartomatous (benign tumors) lesions, which may affect virtually every organ system of the body. <sup>1</sup>

It is inherited in an autosomal dominant manner and results from genetic mutations in the TSC1 (9q34) and TSC2 (16p13.3), which encodes Hamartin and Tuberin proteins, respectively. <sup>2</sup> The genetic mutation may be inherited, or it can occur sporadically. Males and females are equally affected. <sup>3,4</sup>

Activation of the cell cycle control pathway, mTOR pathway, results in the formation of hamartias (misaligned group of dysplastic cells), hamartomas (well-circumscribed group of dysplastic cells), and hamartoblastomas (rare malignant tumors derived from hamartoma). It is a rare disease that affects approximately 1 in 6000 to 1 in 10,000 live births, with an overall occurrence of 1 in 20,000. The median age of presentation is about 7 months. <sup>5</sup>

The prognosis is variable as it depends upon the system involved. Due to the wide spectrum of clinical manifestations, its diagnosis is often delayed. Here, we demonstrate a case of tuberous sclerosis who presented with myoclonic fits and fever.

Correspondence

**Dr. Saleem Iqbal**

Professor

Department of Medicine, Khyber Teaching Hospital,  
Peshawar - Pakistan

**Cell:** +92-333-9125084

**Email:** Drsalmiqbal1@gmail.com

**Date Received:** 24/04/2023

**Date Revised:** 01/02/2025

**Date Accepted:** 18/02/2025

## CASE PRESENTATION

A 14-year-old special child from Peshawar district, the capital city of province Khyber Pakhtunkhwa, Pakistan, who was known epileptic, landed in Emergency department of Khyber Teaching Hospital, Peshawar with myoclonic fits and fever. His pulse was 112/minute, BP was 110/65, and temperature was 101 °F.

His fits could not be controlled with IV midazolam and diazepam, so we injected IV levetiracetam and sodium valproate, which controlled the fits. At the time of admission, his serum electrolytes were normal, serum calcium was 11.42mg/dl, and serum CPK (Creatine Phosphokinase) was 423 U/L.

Upon inquiring his past medical history, he had normal vaginal home delivery with no history of delay cry. However, his developmental milestones were delayed. He had been epileptic from the first year of life. Initially, fits were generalized tonic-clonic, but then they were localized to upper limbs and occurred only during sleep.

His family history revealed that his father was an epileptic with no mental retardation and died at the age of 40 years due to some cardiac disease of which no record was present. His elder brother had fits when he was 7 years old, he received anti-epileptic medicines for a few years. He is off medicine and has been fine for so many years. His elder sister has hypomelanotic macules on her body. One of his paternal uncles is also taking anti-epileptic drugs for seizure control.

Clinical Examination of this child revealed that he had bilateral cataracts in eyes, hypomelanotic macules, and ash leaf spots on skin on various parts of his body, as shown in the pictures, which were taken with the permission of the patient and his parents.

His laboratory investigations showed raised C-reactive protein (CRP) of about 32.65mg. Complete Blood count, serum PTH (Parathormone), and serum TSH were in normal range. Serum calcium, albumin, and magnesium were normal. However, his serum vitamin B12 level were low (62.85pg/ml with normal value of 190-950pg/ml).

His CT scan Brain was ordered, which showed multiple calcified sub-ependymal tubers along both lateral ventricles. Calcified subcortical tubers were also seen in the right occipital and frontal lobe. However, there was no midline shift. MRI brain (with contrast) revealed sub-ependymal nodules along both lateral ventricles (figure 5).

There was a calcified lesion (hamartoma) in the right occipital lobe and a (subcortical) hamartoma right frontal lobe. Abdominal ultrasonography was ordered to look for renal Angiomyolipomas, the report of which depicted bilateral renal cysts. His ECG and Echocardiogram were both normal.

His clinical features showed the classic triad (Vogt's triad) of tuberous sclerosis. His CT scan and MRI brain reports were also suggestive of tuberous sclerosis disease. He was diagnosed with Tuberous sclerosis disease based on diagnostic criteria which includes major and minor features.

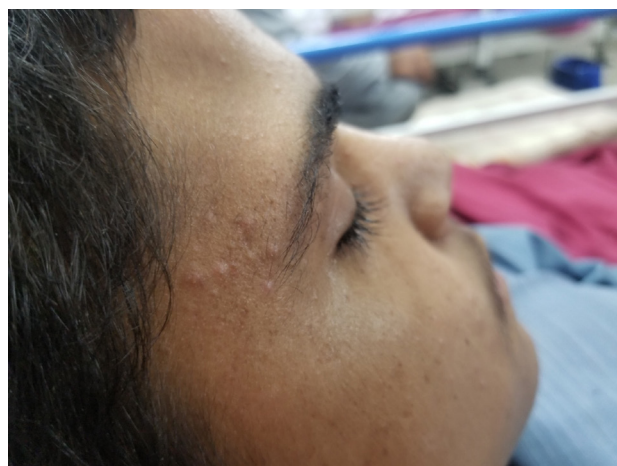**DISCUSSION**

Tuberous Sclerosis Complex presents with a wide spectrum of clinical findings. The signs and symptoms continue to keep on developing over a patient's lifetime. <sup>2</sup> Neurological deficits like seizures, intellectual disability, and autism spectrum disorders are common. <sup>1</sup>

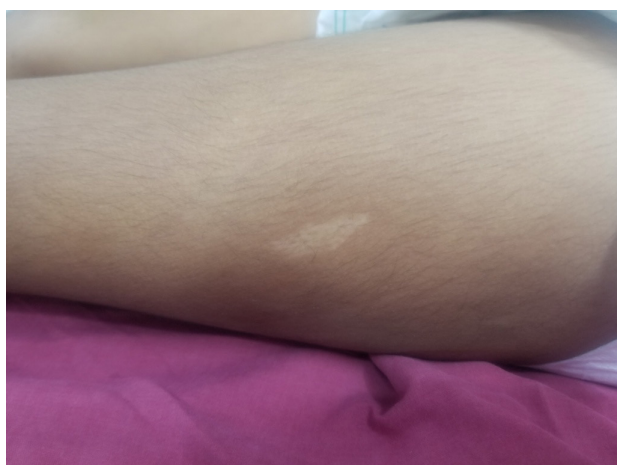A case series that comprised 125 cases reported seizures being the most common presentation in early

**Table No 1: Clinical Diagnostic Criteria for Tuberous Sclerosis Complex**

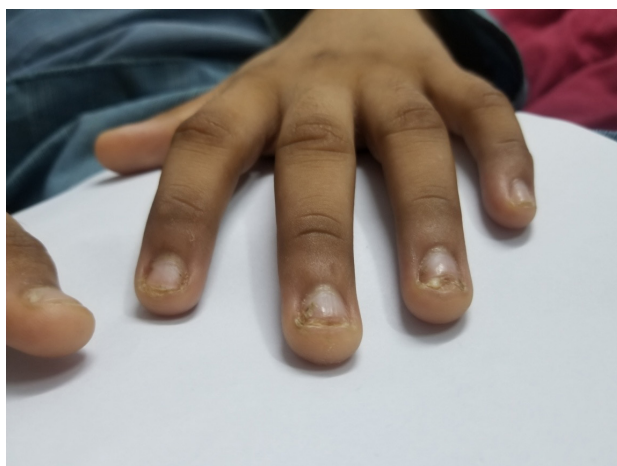MAJOR FEATURES	MINOR FEATURES
Hypomelanotic macules (≥3 and at least 5 mm in diameter)	Confetti skin lesions
Angiofibromas (≥3) or fibrous cephalic plaque	Dental enamel pits (more than 3)
Ungual fibromas (≥2)	Intraoral fibromas (≥2)
Shagreen patch	Retinal achromic patch
Multiple retinal hamartomas	Multiple renal cysts
Cortical dysplasias	Nonrenal hamartomas
Subependymal nodules	
Subependymal giant cell astrocytoma	
Cardiac rhabdomyoma	
Lymphangiomyomatosis	
Angiomyolipomas (≥2)	



**Figure 1: Skin Lesions**



**Figure 2: Hypopigmentation**



**Figure 3: Nails examination**

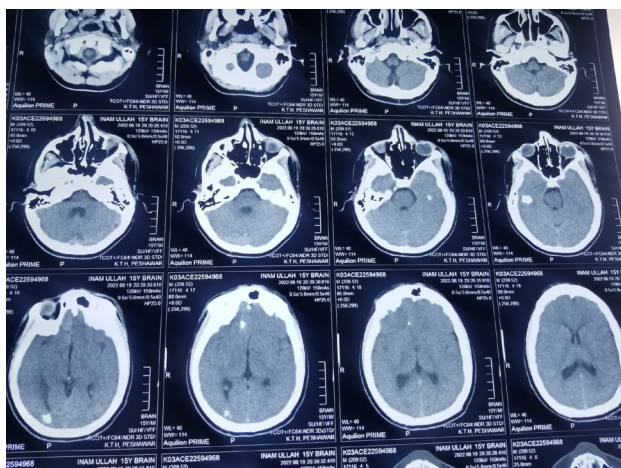


Figure 4: CT Brain Showing Subependymal Tubers

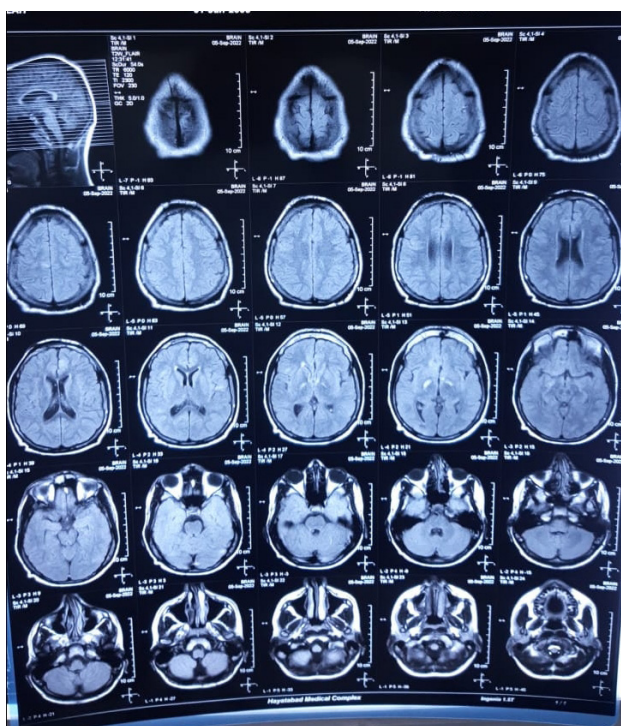
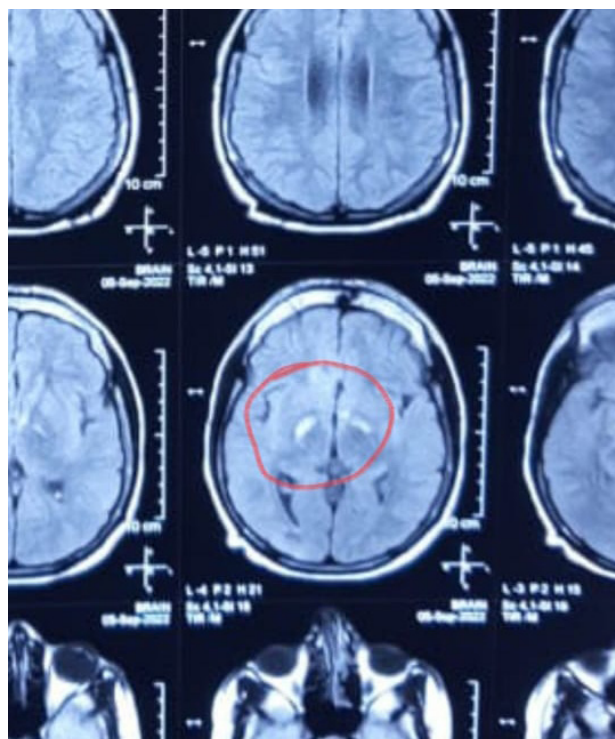


Figure 5 (a): MRI Brain Showing Hamartomas

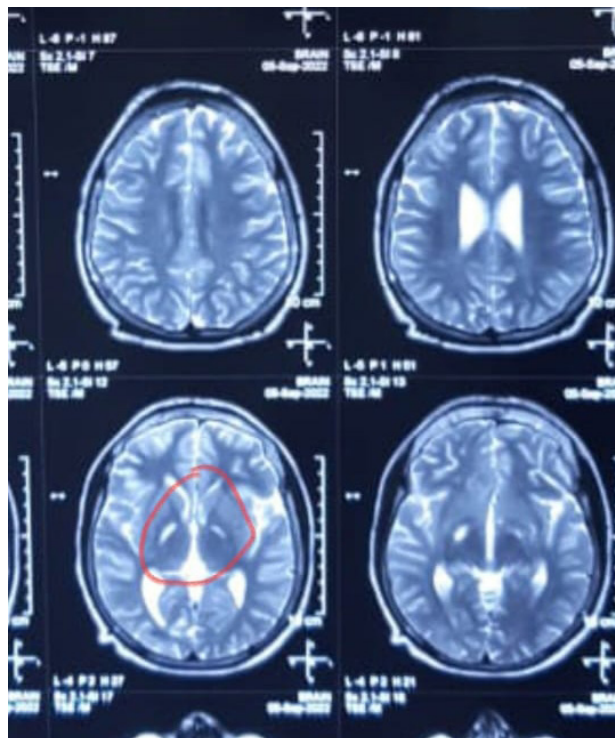


Figure 5 (b): MRI Brain Showing Hamartomas

childhood or infancy, followed by cardiac rhabdomyomas.<sup>5</sup> As it involves multiple systems, its clinical features include neuronal lesions, dermatological, cardiac, ophthalmic, renal, and pulmonary manifestations. However, the disease is characterized by classic triad (Vogt's triad) which includes seizures, mental retardation and adenoma sebaceum (angiofibroma).<sup>6,7</sup>

In the 2012 International Tuberous Sclerosis Complex Consensus Conference, the clinical diagnostic criteria for tuberous sclerosis were revised, which consist of the following major and minor features.<sup>8</sup> A definitive diagnosis is established if a patient has two major features or one major feature with at least 2 minor features, while "possible diagnosis" is predicted in patients with one ma-

or feature or at least 2 minor features.<sup>2,9</sup>

Due to its multi-system involvement, TSC patients may present with a variety of clinical features, which makes its diagnosis a little difficult. Our patient presented with fits and low grade fever; the clinical examination revealed hypomelanotic macules, ash leaf spots, and bi-

lateral cataracts. Bilateral renal cysts were found on the ultrasonogram. CT scan and MRI brain depicted subependymal nodules. All these features confirmed the diagnosis of tuberous sclerosis disease.

The management and treatment of tuberous sclerosis disease focus on providing a good quality of life to patients with lesser adverse effects. The main complaint of tuberous sclerosis patients is seizures, which require long-term therapy. Vigabatrin is the drug of choice for infantile spasm and children with TSC. Focal seizures can be treated with narrow spectrum agents such as oxcarbazepine. Sirolimus and Everolimus are mTOR kinase inhibitors and are approved for use in tuberous sclerosis disease. Furthermore, surgical care for seizures in patients with TSC can be considered, which includes focal cortical resection, corpus colostomy, or Vagus nerve stimulation.

Our patient was managed with Carbamazepine, Levitracetam, and Benzodiazepine. He was discharged when his condition improved.

Since TSC is a lifelong condition and prognosis varies from person to person. There is no curative treatment, however, symptoms can be treated so that patients can lead a better life. Complications that occur in major organ systems are a cause of mortality. Evaluation for TSC-associated neuropsychiatric disorders (TAND) should be done.

## CONCLUSION

Tuberous sclerosis is a rare genetic multisystem disorder that persists throughout the life. It sometimes presents with such mild symptoms that the patient is not diagnosed until adulthood. Sometimes, patients present with severe complications such as cardiac rhabdomyomas and pulmonary manifestations, which can consequently lead to death. Hence, early diagnosis and prompt treatment are necessary to prevent life-threatening complications so that the quality of life of patients can be improved.

## REFERENCES

1. De Waele L, Lagae L, Mekahli D. Tuberous sclerosis complex: the past and the future. *Pediatr Nephrol*. 2015 Oct;30(10): 1771-80.
2. Northrup H, Krueger DA; International Tuberous Sclerosis Complex Consensus Group. Tuberous sclerosis complex diagnostic criteria update: recommendations of the 2012 International Tuberous Sclerosis Complex Consensus Conference. *Pediatr Neurol*. 2013 Oct;49(4):243-54.
3. Sadowski K, Kotulska K, Schwartz RA, Jóźwiak S. Systemic effects of treatment with mTOR inhibitors in tuberous sclerosis complex: a comprehensive review. *J Eur Acad Dermatol Venereol*. 2016 Apr;30(4):586-94.
4. DiMario FJ Jr, Sahin M, Ebrahimi-Fakhari D. Tuberous sclerosis complex. *Pediatr Clin North Am*. 2015 Jun;62(3):633-48.
5. Yates JR, Maclean C, Higgins JN, Humphrey A, le Maréchal K, Clifford M, Carcani-Rathwell I, Sampson JR, Bolton PF; Tuberous Sclerosis 2000 Study Group. The Tuberous Sclerosis 2000 Study: presentation, initial assessments and implications for diagnosis and management. *Arch Dis Child*. 2011 Nov;96(11):1020-5.
6. Rodrigues DA, Gomes CM, Costa IM. Tuberous sclerosis complex. *An Bras Dermatol*. 2012 Mar-Apr;87(2):184-96.
7. Hinton RB, Prakash A, Romp RL, Krueger DA, Knilans TK; International Tuberous Sclerosis Consensus Group. Cardiovascular manifestations of tuberous sclerosis complex and summary of the revised diagnostic criteria and surveillance and management recommendations from the International Tuberous Sclerosis Consensus Group. *J Am Heart Assoc*. 2014 Nov 25;3(6): e001493. doi: 0.1161/JAHA.114.001493.
8. Roach E, Gomez M, Northrup H. Tuberous sclerosis complex consensus conference: revised clinical diagnostic criteria. *J Child Neurol*. 1998; 13:624-628.
9. Krueger DA, Northrup H., International Tuberous Sclerosis Complex Consensus Group. Tuberous sclerosis complex surveillance and management: recommendations of the 2012 International Tuberous Sclerosis Complex Consensus Conference. *Pediatr Neurol*. 2013 Oct;49(4):255-65.



This work is Licensed under a Creative Commons Attribution-(CC BY 4.0)